

PRACTICAL
HUMAN ANATOMY

WEISSE

2

THIRD EDITION

EST.	C
3	
No.	11

A.E. HANSON,
PHILA, PA.

Med Dep 92.
M D





CLASS. WM34
(W432p
4888
v.2

LOWER EXTREMITY.

NINTH DISSECTION.

ANTERIOR OF THIGH.

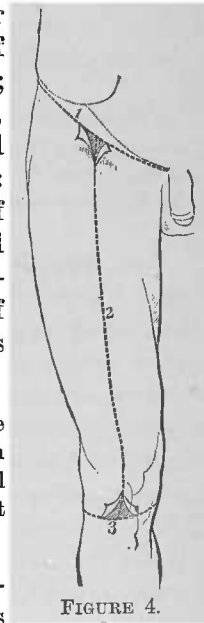
DISSECTION.—Place a block under the pelvis to raise the proximal ends of the lower extremities; extend the limbs at full length with the heels upon the table.

Terms of Relation.—Those applied are: the general terms *anterior* and *posterior* (page 2); the special terms *proximal* and *distal* (toward and from the trunk, respectively); *inner* and *outer* (to the respective lateral surfaces); also, the compound terms *antero-inner* and *outer*, and *postero-inner* and *outer*.

Bones and Bone Areas, Plate 59 and Fig. 1, Plate 91.—The bone surfaces of the dissection are: the anterior border of the ilium and the exterior surfaces of the os pubis and ischium of the os innominatum; the anterior surfaces of the femur, the patella, and of the proximal ends of the tibia and fibula. The areas for muscle attachments are: of the os innominatum, at the anterior border of its ilial and the exterior of its pubic and ischial portions; of the femur, its anterior and postero-inner surfaces; of the patella, its borders; of the tibia, the antero-inner and outer surfaces of its proximal end.

DISSECTION.—The skin incisions for this dissection are indicated in Fig. 4, lines 1, 2 and 3. When this dissection is consecutive to that of the abdomen, skin incision 1 will have been made, as the line of the same describes about that of Poupart's ligament.

1. Subcutaneous Tissue.—This plane of tissue varies in thickness; it consists of two layers—superficial and deep—between which the superficial veins and nerves ramify.



DISSECTION.—Over the patella determine a bursa. Along the inner area of the limb find the internal saphenous vein, and follow its tributary branches. Dissect out, when present, the saphenous lymphatic glands in the proximal quarter of the dissection area.

2. Bursa over the Patella, Plate 60.—At the anterior surface of the patella is a well-marked subcutaneous bursa.

3. Internal Saphenous Vein.—This is a large subcutaneous vein, which has a proximal course from the inner side of the knee along the inner side of the thigh, to the saphenous opening (page 109) in the fascia (lata) of the region, where it enters to empty into the femoral vein. In its course it receives tributary subcutaneous veins from the anterior and posterior areas of the thigh; also the recurrent subcutaneous veins from the inferior antero-lateral areas of the abdominal parietes (page 44; Plate 22).

4. Saphenous Lymphatic Glands.—These glands are clustered about the saphenous opening. They receive lymphatic vessels from the areas contributing tributary veins to the internal saphenous vein. Their efferent vessels penetrate to the deeper glands through the saphenous opening.

DISSECTION.—Clear away the saphenous lymphatic glands, being careful not to destroy the boundaries of the saphenous opening. Determine the points of emergence through the fascia lata of the superficial arteries. Cut away the tributary veins of the internal saphenous vein.

5. Subcutaneous Arteries.—The areas of distribution of the recurrent branches of the femoral artery have already been described (page 44) and illustrated (Plate 22). At this time we only desire to recognize, that they—the superficial epigastric, the superficial circumflex iliac and the superior external pudic—emerge from beneath the fascia lata, through or in the vicinity of the saphenous opening. The inferior external pudic artery perforates the pubic portion of the fascia lata, close to the femoro-scrotal groove, for distribution to the scrotum. Upon the anterior surface of the thigh small arterial twigs will be found to emerge through the fascia lata.

DISSECTION.—Trace the cutaneous nerves in their distal course through the subcutaneous tissue.

6. External Cutaneous Nerve.—This nerve becomes subcutaneous at a variable point inferior to the anterior superior spinous process of the ilium. It distributes to the anterior and posterior surfaces of the outer border of the thigh.

7. The Middle Cutaneous Nerve.—This branch of the anterior crural nerve emerges through the fascia at the anterior face of the thigh, from which point it continues subcutaneously to the knee.

8. The Internal Cutaneous Nerve.—This nerve, branch of the anterior crural, emerges, by several branches, through the fascia lata, at the inner and anterior areas of the thigh.

DISSECTION.—Clear the surface of the fascia free of subcutaneous tissue, allowing the cutaneous nerves and vessels to remain upon it.

9. Fascia Lata.—This is the special name given to the fascia of the thigh. It is a thick sheet of fibrous tissue, which swathes the limb; having its proximal attachments to Poupert's ligament, the linea-ilio pectinea, the pubic arch, the tuberosity of the ischium, the posterior surfaces of the coccyx and sacrum, and the exterior lip of the crest of the ilium; and its distal attachments to the inner and outer tuberosities of the proximal end of the tibia, the proximal end of the fibula and the fascia of the leg.

DISSECTION.—Determine the two anterior proximal planes of the fascia lata. Follow the internal saphenous vein to the saphenous opening; define the borders of the opening, and also the cribriform fascia, which closes the same. Seek the crural branch of the genito-crural nerve, coming through the opening.

10. Saphenous Opening.—This opening or deficiency in the fascia lata results, from the splitting of the fascia, at the inner side of the proximal end of the thigh: an outer, superficial portion—the iliac—is attached to Poupert's ligament; an inner, deep portion—the pubic—is attached to the superior border of the horizontal ramus of the os pubis. The iliac portion lies anterior to the femoral vessels, with its inner border upon the femoral vein, where it is curved to form the superior, the outer, and the inferior limits of the opening—the *falciform edge*; the pubic portion passes posterior to the femoral vessels. The two planes meet, and join at the superior and inferior limits of an ovoid opening, which affords transit to the internal saphenous

nous vein, lymphatic vessels, the crural branch of the genito-crural nerve, and some of the recurrent branches of the femoral artery. From the exterior of the internal saphenous vein to the borders of the opening, the deep layer of the subcutaneous tissue closes the same; this portion of the subcutaneous tissue is perforated by vessels and lymphatics, giving it a sieve-like character, hence its special name of *cribriform fascia of the saphenous opening*.

11. Genito-Crural Nerve.—The crural branch of this nerve (page 78) passes beneath Poupart's ligament, and emerges upon the fascia lata, through the saphenous opening, to distribute to the skin of the proximal third of the anterior face of the thigh.

DISSECTION.—Section the saphenous vein about two inches from the saphenous opening; also cut the nerves in the subcutaneous plane, close to their points of perforation of the fascia lata. Clear the surface of the fascia of all portions of veins and nerves. Incise the fascia in the same line as the skin incisions (Fig. 4, page 107), and reflect lateral flaps of the same.

12. Sartorius Muscle, Plates 59 and 61.—This superficial muscle crosses obliquely from the outer to the inner side of the limb, between its proximal attachment at the anterior border of the os innominatum, inferior to the anterior superior spinous process of the ilium, to its distal attachment at the inner tuberosity of the tibia.

13. Tensor Vaginæ Femoris Muscle, Plate 61.—This is situated at the outer side of the proximal third of the thigh. Its proximal attachment is to the os innominatum, posterior and inferior to the anterior superior spinous process of the ilium; its distal end is attached to the fascia lata in the proximal half of the thigh.

14. Rectus Femoris Muscle, Plate 61.—This muscle occupies a plane deeper than the two previous muscles; it emerges upon the anterior face of the thigh into the distal angle formed between them and continues to the knee.

15. Vastus Externus Muscle.—This is the muscle to the outer side of the rectus femoris and distal to the tensor vaginæ femoris; it swathes around the outer surface of the femur down to the knee.

16. Vastus Internus Muscle.—The distal angle, formed between the sartorius and the rectus femoris, is occupied by this muscle; it winds over the inner surface of the femur down to the knee.

17. Gracilis Muscle, Plates 59 and 61 to 65 inclusive.—This flat, ribbon-like muscle extends along the inner face of the thigh; its proximal attachment is at the exterior border of the pubic arch, its distal at the inner tuberosity of the tibia. About the middle of the thigh it becomes contiguous to the sartorius.

18. Adductor Longus Muscle, Plates 59, 61, 62 and 63.—Occupying the proximal angle, formed by the sartorius and the gracilis, is this triangular muscle; its apex or proximal end is attached to the exterior face of the body of the os pubis; its fibres have a distal and oblique course, passing beneath the inner border of the sartorius to the attachment of its base to the shaft of the femur, at the linea aspera (Fig. 1, Plate 91).

19. Adductor Magnus Muscle, Plate 61.—In the interval between the sartorius, the gracilis and the adductor longus, a portion of this muscle appears.

20. Scarpa's Triangle.—This name has been given to the triangular space, which has its base or proximal limit at Poupert's ligament, its apex or distal limit at the angle of meeting of the sartorius and adductor longus, and its outer and inner sides formed by these muscles, respectively. The floor of the space is formed, at its inner portion, by the anterior surface of the pectineus muscle; at its outer portion, by the anterior surfaces of the thigh portions of the psoas magnus and iliacus internus muscles.

DISSECTION.—Clear the surface of the pectineus muscle, respecting, in so doing, the vessels crossing it. Take up the stump of the internal saphenous vein and follow it to the femoral vein. Open the femoral sheath at the proximal ends of the femoral vein and artery, and expose the two vessels and the femoral canal. Clear the surface of the iliacus internus muscle (Plate 61), that presents to the inner side of the proximal end of the sartorius. Follow the stump of the middle and internal cutaneous nerves to the anterior crural nerve; clear the latter nerve as it lies parallel with the femoral vessels, and determine its deep branches.

21. Vessels and Nerves in Scarpa's Triangle.—Within this triangle are to be found, projected from beneath Poupert's

ligament, the femoral vein, the femoral artery, the femoral canal and the anterior crural nerve. The two vessels and the canal are contained in the femoral sheath, with only a thin fibrous septum between them. At its proximal end the *femoral vein* is to the inner side of the artery; toward the apex of the triangle it passes posterior to the artery. To the outer side of the vein is the *femoral artery*; within the triangle it gives off its recurrent branches, which perforate the fascia lata (page 108), to pass into the subcutaneous plane of the abdominal parietes and to the external genitalia—the superficial circumflex iliac, the superficial epigastric, and the superior and inferior external pudics; the profunda femoris artery is also given off from its posterior surface, at a variable distance from Poupart's ligament. To the inner side of the proximal end of the femoral vein a short canal exists—the *femoral canal*; it extends as a pouch of the femoral sheath, and is about one inch in length. At its proximal limit the femoral canal opens into the abdominal cavity by the *femoral ring*, which is bounded, as follows: by the femoral vein, externally; the superior border of the horizontal ramus of the os pubis, inferiorly; Gimbernat's ligament, internally; and Poupart's ligament, superiorly. The *anterior crural nerve* lies to the outer side of the femoral artery, being separated from it by a slight interval; to it can be traced the middle and internal cutaneous nerves; the internal saphenous nerve may be followed down from it to the femoral artery; its deep or muscular branches take a distal course, disappearing beneath the sartorius muscle; a branch to the pectineus muscle passes internally, in a plane posterior to the femoral vessels.

DISSECTION.—Section the sartorius muscle (Plate 61) and reflect its portions, superiorly and inferiorly. (The reflected portions of the sartorius muscle should not be cut close to their attachments, as is represented in Plate 62). Abduct the thigh and semiflex the knee, resting the foot upon its outer border.

22. Hunter's Canal, Plate 62.—Beneath the portion of the sartorius muscle distal from Scarpa's triangle, a layer of fibrous tissue (a portion of the sheath of the sartorius) stretches from the anterior surfaces of the adductor longus and magnus muscles to the inner surface of the vastus internus muscle. A triangular canal—*Hunter's Canal*—is formed as follows: by the fascia of the sartorius anteriorly and to the inner side; the

adductor longus and magnus muscles posteriorly; the vastus internus muscle to the outer side.

23. Internal or Long Saphenous Nerve.—This nerve is given off from the inner side of the anterior crural; it accompanies the femoral artery into Hunter's canal.

DISSECTION.—Extend the limb; section the tensor vaginae femoris muscle at its distal attachment to the fascia lata and reflect it superiorly; in raising it from its bed note the branch from the inferior gluteal nerve, that enters its deep surface. Clear the muscle surfaces beneath the tensor vaginae femoris, preserving the ramifications of arteries.

24. Gluteus Medius and Minimus Muscles, Plates 62, 63, 64 and 65.—The anterior borders of these two muscles present proximal to the trochanter major and to the outer side of the proximal end of the rectus femoris muscle.

25. Rectus Femoris Muscle, Plates 59, 61 and 62.—This is the superficial, anterior, straight muscle of the thigh; its proximal attachments are to the inferior spinous process of the os innominatum and by a reflected tendon, from a point upon the superior surface of the cotyloid cavity or acetabulum of the same bone; its distal attachment is at the base or proximal border of the patella.

DISSECTION.—Raise the rectus femoris muscle from its bed; be careful not to destroy subjacent nerves. Section it (Plate 62) and reflect its halves, superiorly and inferiorly. In reflecting its proximal portion, note its supplying nerve, from the anterior crural; also its arterial supply, from the external circumflex artery. Slit open the fascial wall of Hunter's canal and distinguish the contained vessels and nerves; in doing so the femoral artery and the internal saphenous nerve may be hooked to the inner side, and the nerves to the vastus internus muscle to the outer side, in order to bring into view the femoral vein and the profunda femoris artery.

26. Contents of Hunter's Canal, Plate 63.—The *femoral artery* continues from Scarpa's triangle to the inner side of the shaft of the femur, entering Hunter's canal, where it lies upon the anterior surfaces of the adductor longus and magnus muscles; as lodged in the canal, it gives off two or three branches to the vastus internus muscle. At the distal end of the canal the artery passes through the femoral opening in the adductor magnus muscle. The *femoral vein* takes the same

course as the artery ; at first it lies posterior to and then passes to the outer side of the artery, where it lies against the vastus internus muscle. The *internal saphenous nerve* accompanies the femoral vessels through the canal, upon the anterior and outer surface of the femoral artery ; it leaves the artery at its distal end, anterior to the adductor magnus muscle, to join the internal saphenous vein, at the distal side of the knee.

DISSECTION.—Expose the profunda femoris artery and its vein, at the proximal side of the adductor longus muscle, in a plane posterior to the femoral vessels. Note how this artery and vein pass posterior to the adductor longus muscle. Cut away the venæ comites of the profunda femoris artery and its branches.

27. Profunda Femoris Artery.—This artery (vena comes) is a branch from the posterior surface of the femoral artery, at a variable point in the course of the latter through Scarpa's triangle. It takes a distal course in a plane posterior to its parent trunk, having its vein to its inner side ; it passes to the plane posterior to the adductor longus muscle. Its branches are the external circumflex, the internal circumflex, and the three perforating.

DISSECTION.—Clear the surfaces of the vastus externus, the crureus, and the vastus internus muscles, respecting, in so doing, the nerves and arteries, which enter their proximal portions. Trace the muscle branches of the anterior crural nerve and the distribution of the external circumflex artery ; trim away the venæ comites of the arteries.

28. Vastus Externus Muscle, Plate 59, Fig. 1, Plate 91, and Plates 61 to 65 inclusive.—The anterior surface of this muscle was before referred to (page 111) ; it is now fully exposed (Plate 63). It is attached to the femur, from a point posterior to and distal from the trochanter major, to the entire length of the outer lip of the linea aspera down to the external condyle ; it winds around the outer surface of the shaft of the femur, having an anterior free border ; it blends, at its distal end, with the tendon of the rectus femoris.

29. Crureus Muscle, Plates 59 and 63.—This is the anterior, deep, straight muscle of the thigh ; it is attached to the proximal two-thirds of the anterior surface of the shaft of the femur ; at its distal end, it blends with the tendon of the rectus femoris.

30. Vastus Internus Muscle, Fig. 1, Plate 91, and Plates 59, 61, 62 and 63.—This muscle occupies the inner face of the shaft and inner condyle of the femur; it is attached to the inner lip of the linea aspera, from which it winds around the inner surface of the femur, to fuse with the crureus, and blend, at its distal end, with the tendon of the rectus femoris. Compared with the vastus externus: it is the smaller of the two—that is, it does not rise as high upon the shaft of the femur; it covers the inner condyle of the femur, forming a cushion of muscle upon it, while the vastus externus does not cover the condyle of its side.

31. Quadriceps Extensor Femoris Muscle and its Compound Aponeurosis, Plates 59 and 61 to 65, inclusive.—The rectus femoris, the vastus internus, the crureus, and the vastus externus blend at their distal extremities, thus forming a quadriceps (four-headed) muscle, which is attached to the base and borders of the patella. Distal to the patella the quadriceps tendon is continued as a compound aponeurosis, which caps the anterior and the two lateral areas of the knee-joint, attaching itself to the tubercle of the patella (the so-called ligamentum patellæ) and to the inner and outer tuberosities of the proximal end of the tibia. The proximal portion of the aponeurosis is lined by the anterior ligament of the knee-joint; it is separated from it, opposite the joint, by a layer of fat.

32. External Circumflex Artery, Plate 63.—This artery, branch of the profunda femoris, distributes distal branches to the muscles of the quadriceps group; a proximal branch winds around the outer surface of the hip to the muscles of the gluteal region.

33. Muscle Branches of the Anterior Crural Nerve, Plates 61, 62 and 63.—From the deeper portion of the trunk of the anterior crural nerve, where the same is lodged in Scarpa's triangle, branches are given off, which may be traced to the following muscles: the sartorius, the pectineus (page 112), the rectus femoris, the vastus internus, the crureus and the vastus externus.

DISSECTION.—Section the aponeurosis of the quadriceps muscle by a curved incision to the distal side of the patella (Plate 63); be careful not to cut into the joint, but expose a layer of fat, present between the aponeurosis and the

anterior ligament of the joint. Make a longitudinal incision through the substance of the vastus externus muscle, down to the shaft of femur, as shown in Plate 64. Semiflex the knee-joint and abduct the thigh. Reflect the aponeurosis from the inner side of the knee-joint proximally, and to the outer side, cutting the anterior ligament of the joint at the circumference of the articular surface of the patella. Continue the proximal reflection of the vastus internus, the crureus, and the vastus externus (inner portion of) muscles, being careful to leave, *in situ*, the proximal portion of the redundant anterior ligament of the joint, with the attachment to it of the subcrureus muscle; trace the latter muscle to its proximal attachment. Cut the reflected muscles, and portion of muscle (vastus externus), from the shaft of the femur; cut the branches of the anterior crural nerve and those of the external circumflex artery, at their trunks, respectively. Carefully cut away the vastus internus muscle from its linea aspera attachment (Fig. 1, Plate 91).

34. Subcrureus Muscle, Plates 59, 64, and 65.—This is a small muscle attached, at its proximal end, to the anterior surface of the distal third of the shaft of the femur; at its distal end, to the anterior ligament of the knee-joint.

35. Proximal Portion of the Anterior Ligament of the Knee-Joint, Plates 64 and 65.—This ligament lines the tendon and aponeurosis of the quadriceps extensor femoris muscle; it is adapted to the two conditions of the joint, flexion and extension: in the position of flexion it is drawn taut over the anterior surface of the condyles of the femur; in extension it appears redundant, at the proximal side of the base of the patella, where it is drawn up by the subcrureus muscle.

DISSECTION.—Section the femoral artery and vein distal to their profunda femoris branches (Plate 63); cut them also at the proximal side of the femoral opening in the adductor magnus muscle (Plate 64). Section the adductor longus muscle (Plate 63), and reflect its proximal portion to its pubic attachment, where it may be cut or, better, turned off upon the symphysis pubis; in raising it do not disturb the branches of the anterior portion of the obturator nerve beneath it; recognize the branch of this portion of the obturator nerve, that supplies the adductor longus muscle—entering its posterior surface. Reflect the distal portion of the adductor longus to its femoral attachment (Fig. 1, Plate 93) and cut it close to the bone. Trace the profunda femoris artery and its internal circumflex branch; its perforating and its muscle branches; cut away their venæ comites.

36. Profunda Femoris Artery, Plates 64 and 65.—This artery was before recognized as a branch of the femoral in Scarpa's triangle, as passing posterior to the adductor longus muscle (page 114), and as giving off the external circumflex

artery (page 115). At present it is exposed in its course upon the anterior surfaces of the adductor brevis and magnus muscles ; it lies close to, and parallel with the femur, and gives off three branches : the first, the second, and the third perforating. They are called perforating, because they pass through openings in the adductor brevis and magnus muscles, to distribute in the posterior plane of the thigh ; the terminal end of the artery also perforates the adductor magnus muscle. In its course the artery affords muscle branches to the adductor magnus muscle, some of which also pass to the posterior plane of the limb.

DISSECTION.—Turn off the femoral vein over Poupart's ligament ; determine the interspace between the pectineus and the psoas magnus muscles ; make a longitudinal cut through the pectineus, and reflect its proximal portion to its attachment to the horizontal ramus of the os pubis, where it may be cut or turned off. Restore the femoral vein to the surface of the psoas magnus muscle. In reflecting the portion of the pectineus muscle, respect the anterior portion of the obturator nerve and the obturator artery. Trace the branches of the anterior portion of the obturator nerve ; clear the obturator artery ; look for the accessory obturator nerve, which, when present, passes beneath the pectineus muscle.

37. Internal Circumflex Artery, Plates 63 and 64.—This artery is a branch from the inner side of the profunda femoris ; it passes to the inner side of the limb, posterior to the adductor longus muscle, to distribute to the adductor muscles.

38. Pectineus Muscle, Plates 59, 61 to 64 inclusive, and Fig. 1, Plate 93.—This muscle has its proximal attachment to the exterior and superior surfaces of the horizontal ramus of the os pubis of the os innominatum ; thence it has a distal and oblique course, forming the inner portion of the floor of Scarpa's triangle (page 111), to its distal attachment to the femur, at the inner side of the proximal open angle of the linea aspera.

39. Obturator Nerve, Plates 64 and 65.—This nerve, from the lumbar plexus (described page 78, and illustrated Plates 39, 40, 41 and 46), emerges from the pelvis, under cover of the pectineus muscle, at the anterior and inner angle of the thyroid foramen, and anterior to the border of the obturator externus muscle. It divides into two portions, an anterior and a

posterior, which are in contact, respectively, with the anterior and posterior surfaces of the adductor brevis muscle. The anterior portion affords branches as follows: to the adductor longus, the gracilis, and the adductor brevis muscles; a communicating branch to the internal cutaneous nerve (of the anterior crural), which at times (as in Plate 64) has a special cutaneous distribution to the inner face of the leg; an articular branch, which perforates the adductor magnus muscle on its way to the knee-joint.

40. Obturator Artery.—This artery enters the thigh from the pelvis with the nerve. It distributes to the obturator externus and the adductor muscles, and the hip-joint.

DISSECTION.—Clear the surfaces of the adductor brevis and magnus muscles. Define the femoral opening in the distal portion of the adductor magnus. Trace the femoral vein and artery through the opening. Recognize and follow the anastomotic magna branch of the femoral artery.

41. Adductor Brevis Muscle, Plates 59 and 64, and Fig. 1, Plate 91.—This muscle is the third of the adductor group; it is attached to the exterior surface of the pubic arch and to the linea aspera of the femur. It presents openings, close to the shaft of the femur, for the first and second perforating arteries from the profunda femoris.

42. Femoral Opening in the Adductor Magnus Muscle, Plates 64 and 65.—This opening is in the tendinous portion of the distal half of the adductor magnus; through it the femoral artery passes into the popliteal space, becoming the popliteal artery, and the popliteal vein, having a reverse course, becomes the femoral.

43. Anastomotic Magna Artery.—This artery (*venæ comites*) is given off from the femoral, before the latter enters the opening in the adductor magnus muscle. It has a distal course along the inner surface of the knee; it distributes to muscles and anastomoses with the internal articular branches of the popliteal artery.

DISSECTION.—Section the perforating branches of and the terminal portion of the profunda femoris artery; cut the proximal ends of the femoral artery, the femoral vein, and the anterior crural nerve close to Poupart's ligament (Plate 64). Remove the profunda artery with the stumps of the femoral vessels

and the anterior crural nerve. Cut the internal circumflex artery at its origin from the profunda and leave its posterior branch *in situ*. Section the anterior portion of the obturator nerve (Plate 64), the distal ends of its gracilis and articular (knee) branches, and remove the nerves. Section the adductor brevis muscle and reflect its parts; in reflecting its proximal part respect the posterior portion of the obturator nerve posterior to it, and recognize its branch to the muscle, which enters the posterior surface of the same; the distal portion of the muscle should be cut at its attachment at the linea aspera of the femur, trimming out the perforating arteries from their points of muscle perforation. Reflect the distal portion of the pectineus muscle and cut it at its femoral attachment. Cut the obturator artery. Trace branches from the posterior portion of the obturator nerve and from the internal circumflex artery to the adductor magnus muscle. Clean the anterior surface of the adductor magnus and the exposed portions of the obturator externus, the quadratus femoris, the iliacus internus, the psoas magnus, and the semimembranosus muscles; also the exposed area of the capsular ligament of the hip-joint.

44. Posterior Portion of the Obturator Nerve, Plate 65 and Fig. 2, Plate 66.—This portion of the obturator nerve supplies the adductor brevis, the adductor magnus and the obturator externus muscles; sometimes the articular branch to the knee-joint is derived from this portion of the nerve, instead of the anterior portion (page 118; Plate 64).

45. Internal Circumflex Artery.—Branches from this artery distribute upon the anterior surface of the proximal portion of the adductor magnus muscle. Two branches of it pass posteriorly; one to the hip-joint, the other between the contiguous borders of the adductor magnus and the quadratus femoris muscles, to emerge into the posterior plane of the thigh.

46. Adductor Magnus Muscle, Plates 59, 64 and 65; Fig. 2, Plate 66, and Fig. 1, Plate 91.—From its proximal attachment, to the exterior of the ischium of the os innominatum, this muscle spreads to its distal attachment to the entire length of the linea aspera of the femur, along the outer side of the inner lip of the same, and to the inner condyle of the femur. It extends as a septum of muscle from the inner surface of the femur, dividing the inner mass of the thigh into an anterior and a posterior plane, the respective surfaces of the muscle forming the floor of each. It presents openings close to its femoral attachment: three or four proximal ones for the perforating arteries from the profunda femoris (page 117); and a large distal opening—the *femoral*—for the femoral artery and vein (page 118).

47. Iliacus Internus Muscle, Plates 59, 61 to 65 inclusive, and Fig. 1, Plate 91.—The abdominal portion of this muscle was described (page 82), and illustrated (Plates 38 to 41 inclusive, and Plate 44), *in situ*; its abdominal attachment was before shown (Plate 42, and Fig. 1, Plate 45). The muscle is projected from the abdominal cavity, beneath Poupart's ligament, into the anterior plane of the thigh. It bridges over the hip-joint, exterior to the anterior portion of its capsular ligament, and it is attached to the antero-inner surfaces of the proximal end of the shaft of the femur, near the trochanter minor.

48. Psoas Magnus Muscle: Plates 59, 65; Fig. 1, Plate 66; Fig. 1, Plate 91.—The abdominal portion of this muscle was described (page 82), and illustrated (Plates 38 to 41 inclusive) *in situ*; its abdominal attachment was before shown (Plates 42, 43, and 44). The muscle enters the thigh to the inner side, and parallel with, the iliacus internus, and is attached to the femur at the posterior surface of the trochanter minor.

49. Quadratus Femoris Muscle: Plates 59, 65; Fig. 2, Plate 66; and Fig. 1, Plate 91.—A portion of the anterior face of this muscle appears proximal to, and in a plane posterior to, the border of the adductor magnus muscle. Between it and the adductor magnus a branch from the internal circumflex artery passes to the posterior plane of the thigh.

50. Semimembranosus Muscle, Plates 64 and 65.—At the inner side of the distal third of the thigh, a portion of the anterior surface of this muscle appears in the distal angle between the gracilis and the adductor magnus muscles.

DISSECTION.—Section the iliacus internus and the psoas magnus muscles close to their attachments to the femur; reflect them, superiorly, to the brim of the pelvis, where they may be cut; note a large bursa beneath them which should be preserved. Clear the surface of the obturator externus muscle, and determine the proximal portions of the obturator vessels and nerve.

51. Bursa of the Psoas and Iliacus Muscles, Fig. 1, Plate 66.—A large bursa presents between the psoas magnus and iliacus internus muscles and the capsular ligament of the hip-joint; it sometimes communicates with the interior of the joint.

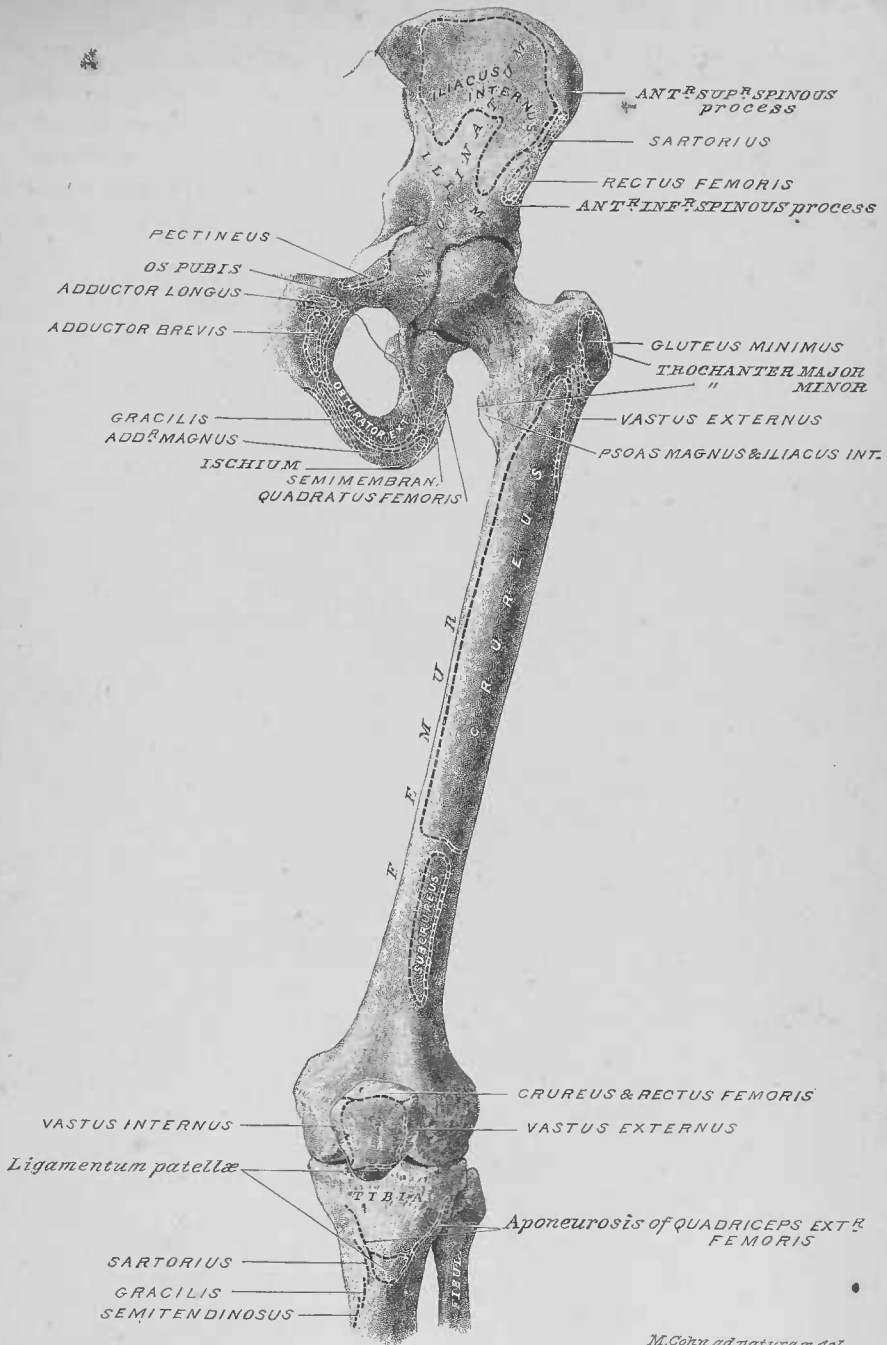52. Obturator Externus Muscle, Plates 59, 64, 65 and 66.—This muscle is attached, internally, to the exterior face of the internal and inferior borders of the obturator foramen, and from the internal half of the obturator membrane (Plate 59); its course is externally, its tendon passing posterior to the hip-joint (Fig. 1, Plate 66).

53. Obturator Nerve, Plate 66.—The posterior portion of this nerve sometimes perforates the obturator externus muscle; more commonly, the anterior and posterior portions of the nerve form a single trunk, which passes out of the pelvis superior to the muscle.

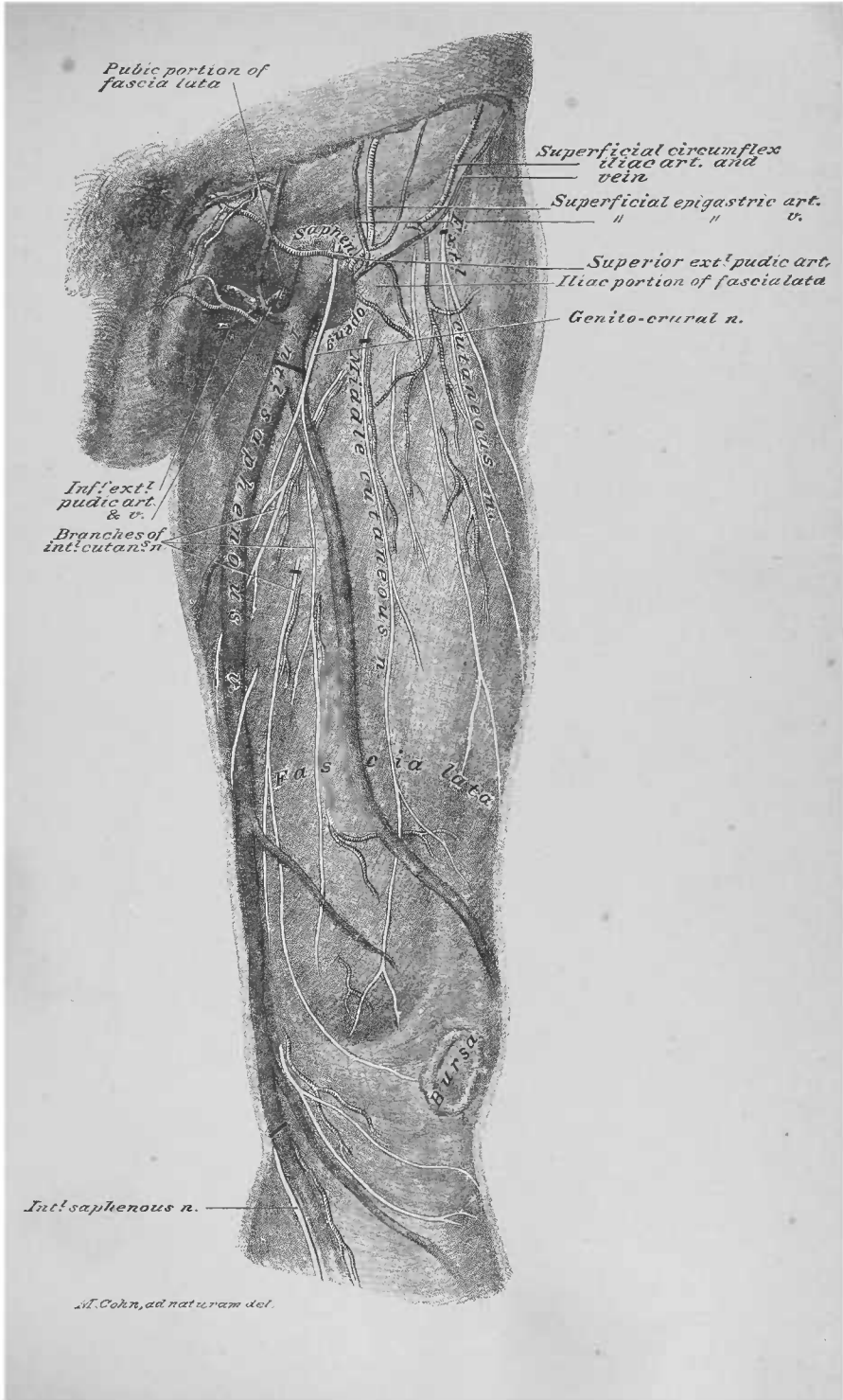
DISSECTION.—Clean the exterior of the anterior portion of the capsular ligament of the hip-joint. Cut the ilial attachment of the rectus femoris muscle close to the bone.

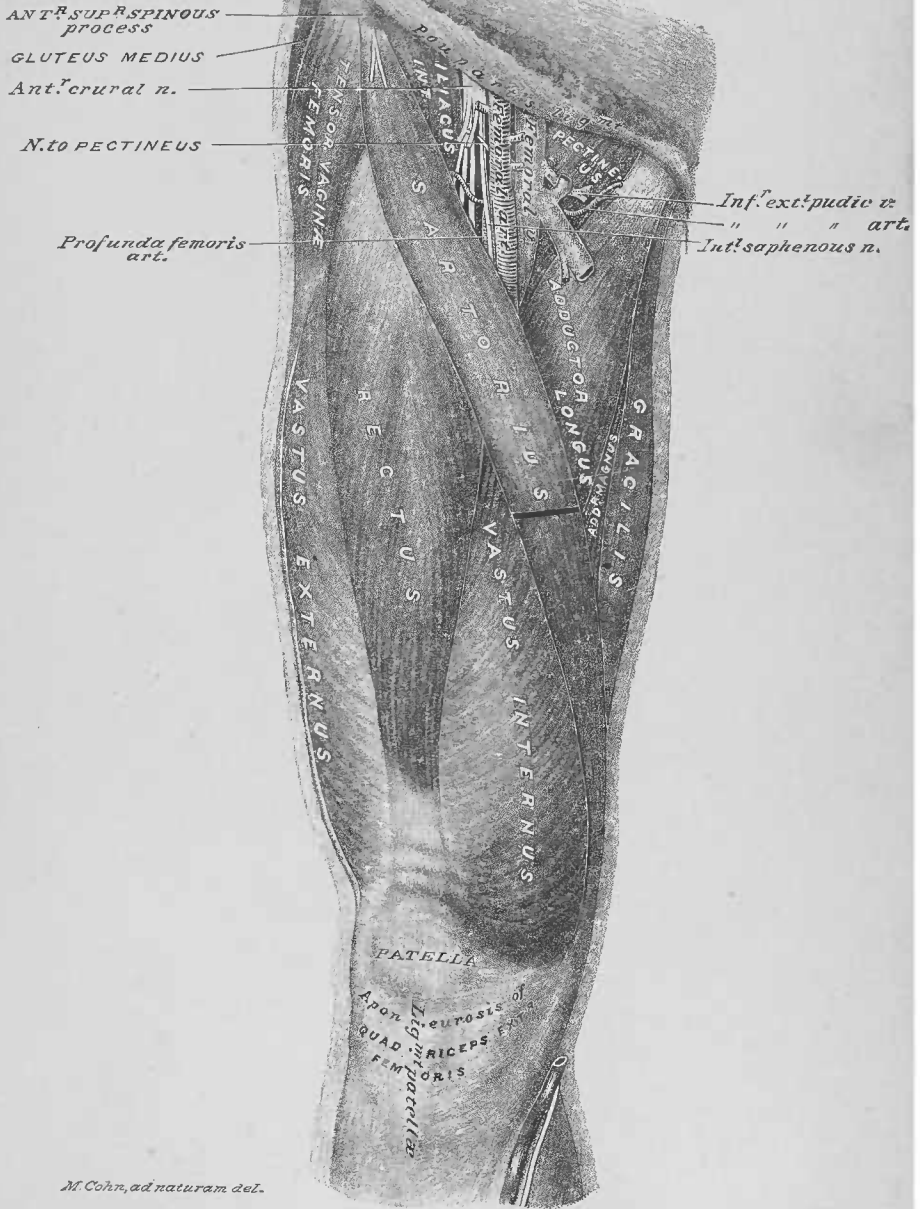
54. Capsular Ligament of the Hip-joint, Fig. 2, Plate 66, and Plates 64 and 65.—The anterior portion of the capsular ligament of the hip-joint has its proximal attachment at the anterior and inner surfaces of the rim of the cotyloid cavity of the os innominatum and its distal attachment to the trochanters and the anterior intertrochanteric line of the femur. This area of the capsular ligament presents three thick longitudinal portions, which may be designated as follows: the ilio-femoral ligament, the ilio-femoral band, and the pubio-femoral band. The *ilio-femoral ligament* has its proximal attachment at the antero-inner border of the rim of the cotyloid cavity of the os innominatum, and the superior surface of the wall of the cotyloid cavity, up to the anterior inferior spinous process of the ilium; its distal attachment is to the inner portion of the anterior intertrochanteric line. The *ilio-femoral band* has its proximal attachment to the superior surface of the wall of the cotyloid cavity, extending up to the anterior inferior spinous process of the ilium; its distal attachment is to the outer portion of the anterior intertrochanteric line of the femur upon the face of the great trochanter. These two fibrous bands, thus diverging inferiorly, form an inverted Y-shaped ligamentous structure, which has been designated by Bigelow as the Y ligament of the hip-joint ("The Mechanism of Dislocation and Fracture of the Hip, etc." By Professor Henry J. Bigelow, M.D., pages 17 and 18). In the interval between the fibrous

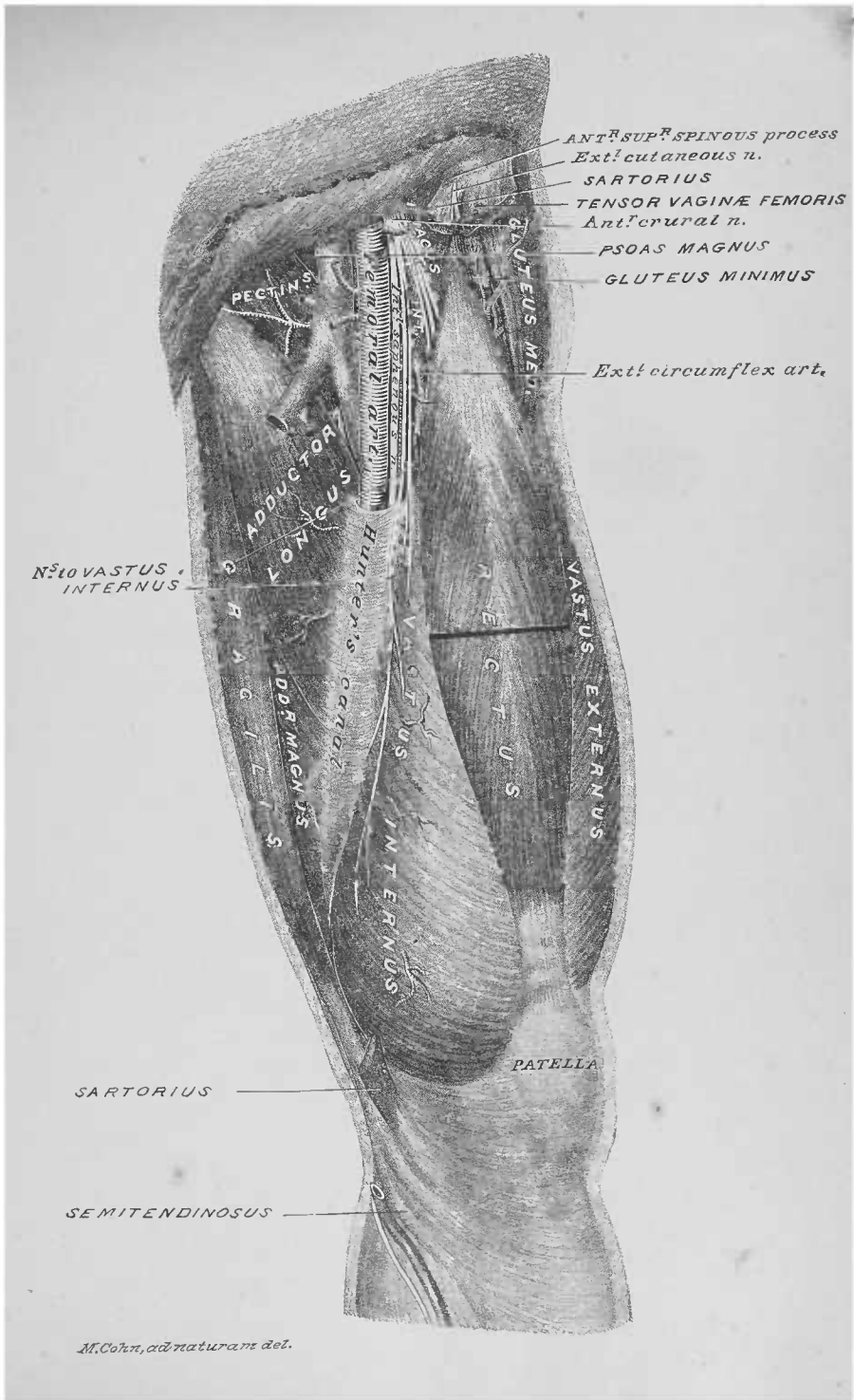
bands, an articular branch of the external circumflex artery perforates the capsular ligament of the joint. Manipulating the joint by external and internal rotation, and by forced extension, these two bands of the Y ligament are made more evident. The *pubio-femoral band* is a sweep of fibrous tissue, that bridges from the exterior face of the horizontal ramus of the os pubis to the trochanter minor.

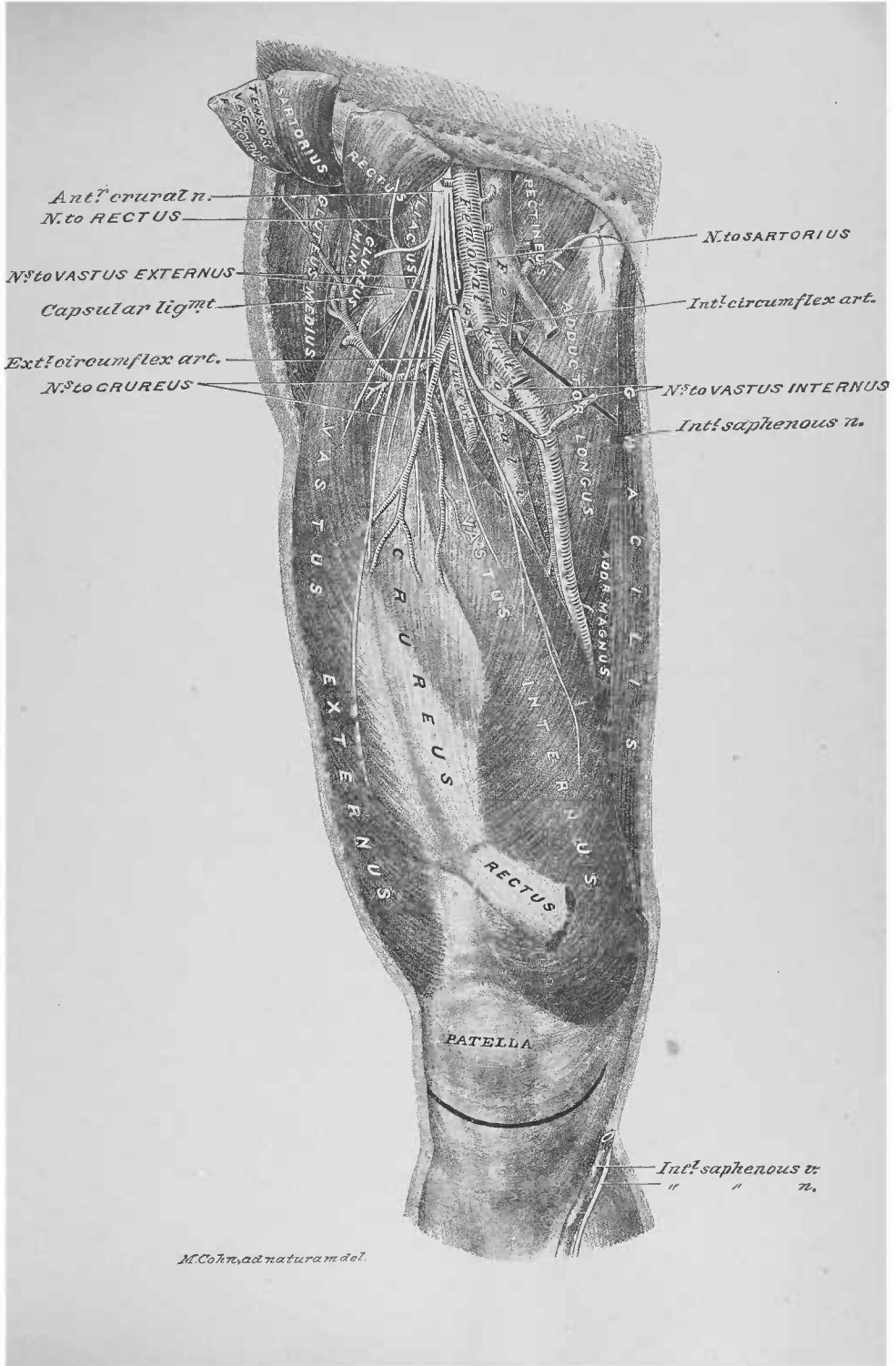

M. Cohn ad naturam del.

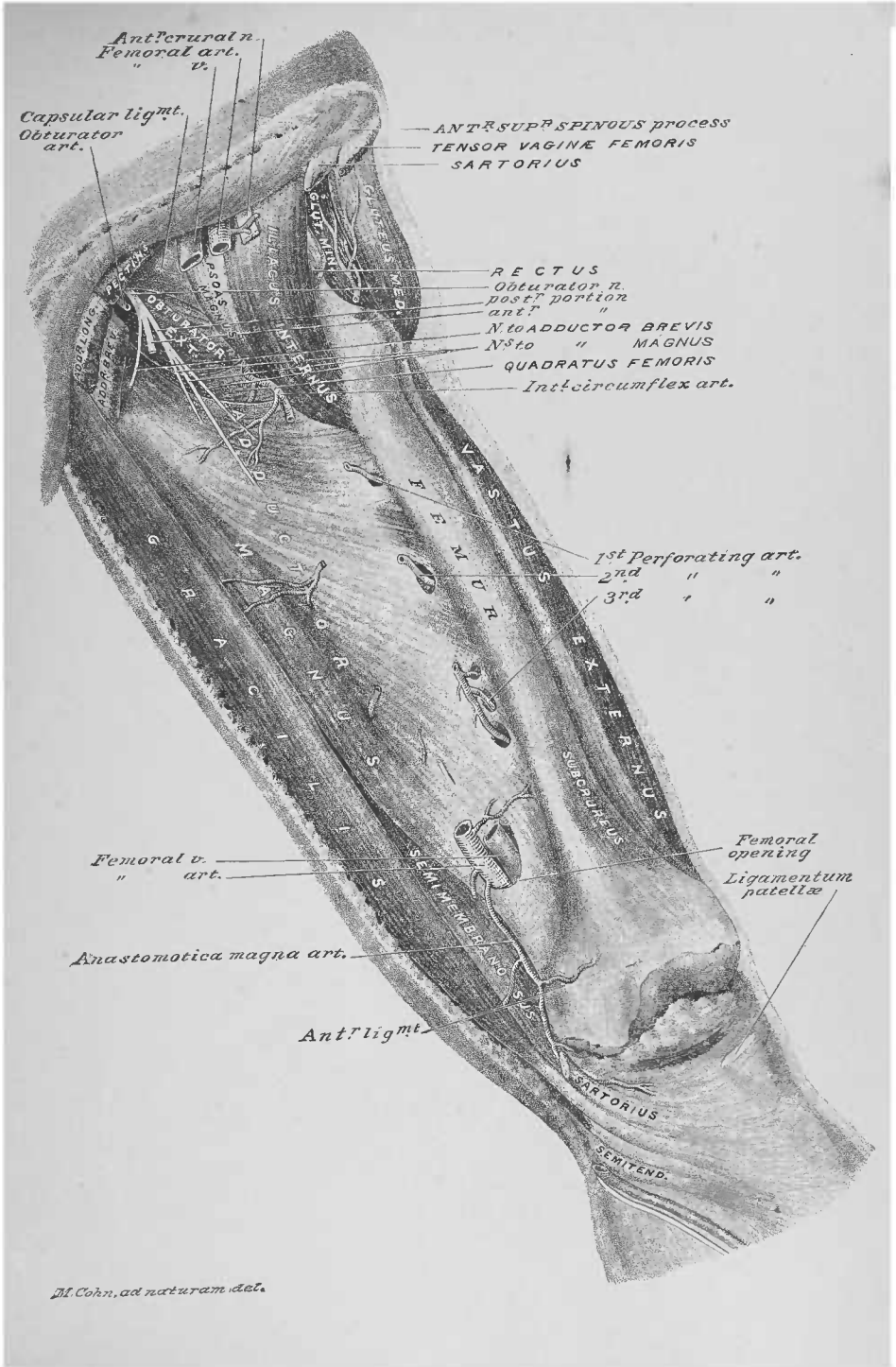








M. C. W. del. ad naturam.



M. Cohn, ad naturam del.

FIG. 1

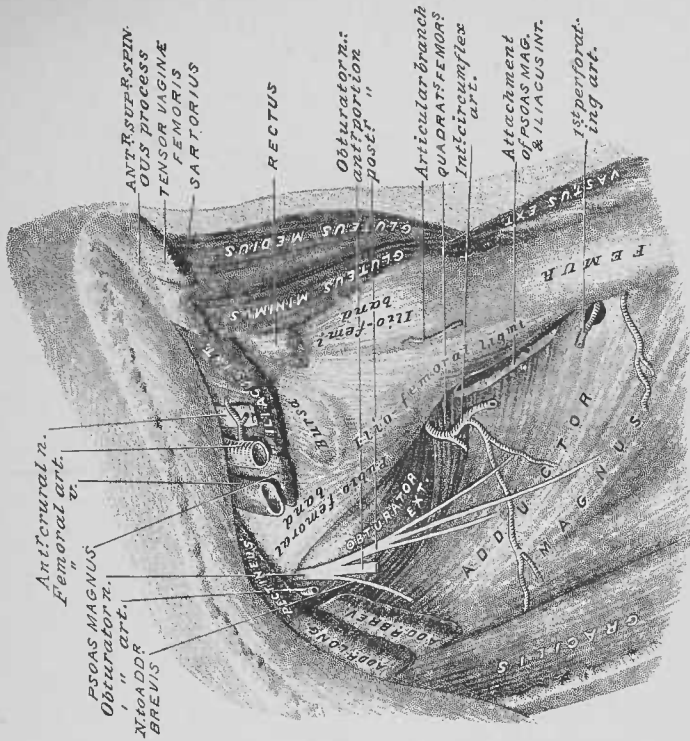
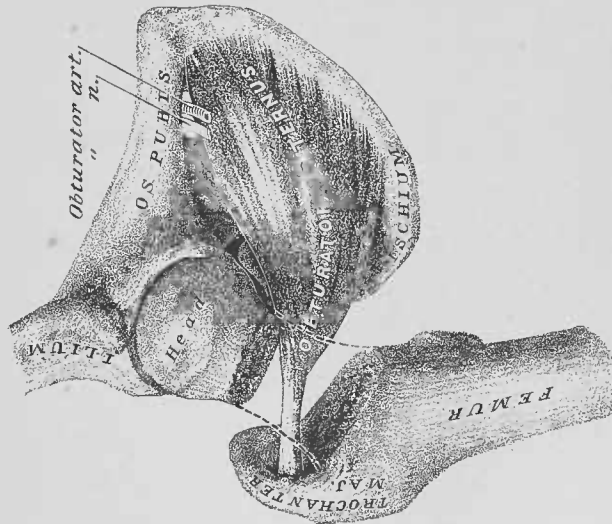


FIG. 2



M. Cohn, ad nat. del.

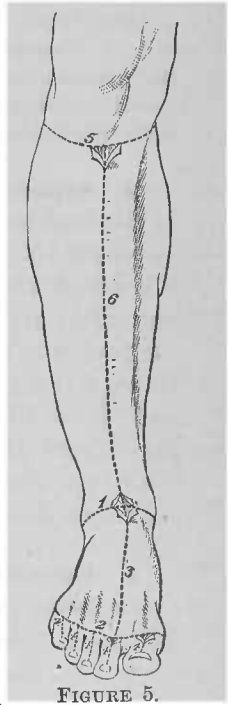
TENTH DISSECTION.

ANTERIOR OF LEG AND DORSUM OF FOOT.

DISSECTION.—For this dissection the two limbs should be supported at the ankles on blocks; tie the great toes together, so as to expose the outer antero-lateral area of the leg and foot.

Terms of Relation.—The terms applicable to both regions are: the general, *inferior*; the special, *proximal* and *distal* (toward and from the trunk). Those for the leg are: *anterior*, *posterior*, *outer*, and *inner surfaces*; *outer antero-lateral* and *inner antero-lateral areas* (including both anterior and outer or inner surfaces, respectively). Those to the foot are: *dorsum* or *dorsal surface*; *plantar surface*; *inner* or *pollex border* or *side*; *outer* or *minim border* or *side*. Those to the toes are: *dorsal*, *plantar*, and *lateral digital surfaces*. The regions of the foot will be spoken of as *tarsal*, *metatarsal*, and *digital*.

Bones and Bone Areas, Plates 67 and 68.—The outer and inner surfaces of the tibia and fibula of the leg; the dorsal surfaces of the bones of the tarsal region of the foot—calcaneum, astragalus, scaphoid, cuneiform (internal, middle, and external), and cuboid; the dorsal surfaces of the bones of the metatarsal region—the five metatarsals; and the dorsal surfaces of the fourteen bones of the digits* form the osseous framework of the dissection. All of these bones, except the astragalus, the scaphoid, the cuboid, and the three



* The bones of the digits will be called by the special French names given to them by Chaussier, anglicized as follows: *phalana* (s.), *phalanges* (pl.), to the five bones of the proximal row; *phalangine* (s.), *phalanges* (pl.), to the four of the middle row; *phalangette* (s.), *phalangettes* (pl.), to the five of the distal row.

cuneiform, afford attachments to muscles. Each metatarsal and each digital bone has a *base* (proximal end), a *shaft*, and a *head* (distal end).

DISSECTION.—Make the skin incisions 1, 2, 3, and 4, 4, 4, 4, of Figure 5; reflect flaps well off of the inner and outer borders of the tarsal and metatarsal regions of the foot, and the dorsal halves of the lateral digital surfaces (Plate 71). Facilitate the turning off of the flaps from the foot by additional skin incisions from the tips of the malleoli, respectively, to the heel.

1. Subcutaneous Tissue of the Dorsum of the Foot and Digits, Plates 69, 70, and 71.—In this tissue subcutaneous veins will be found in a superficial plane, while subcutaneous nerves lie in a deeper one.

DISSECTION.—Dissect out the saphenous arch of veins, their tributary and resultant trunks; expose the subcutaneous distribution of the external saphenous, the musculo-cutaneous, the anterior tibial, the internal saphenous, and the internal calcaneal nerves, upon the dorsum and borders of the foot and the lateral digital surfaces. Clear the fascia of the dorsal surfaces of the foot and digits of subcutaneous tissue, preserving the above veins and nerves, *in situ*.

2. Saphenous Arch.—This venous arch crosses the dorsum of the foot in the distal third of the metatarsal region. At the outer side it is continued by the external saphenous vein (Plate 69), which ascends to the posterior surface of the leg, by winding inferiorly to the external malleolus; at the inner side of the foot, the arch is continued by the internal saphenous vein, which has a proximal course to the inner surface of the distal end of the tibia (Plate 70). The convexity of the arch receives the dorsal collateral digital veins. A variable number of branches leave the concavity of the arch, having a proximal course to the leg.

3. External Saphenous Nerve, Plate 69.—This cutaneous nerve enters the outer border of the foot, inferiorly to the distal end of the fibula. It distributes a dorsal collateral digital branch to the outer lateral digital surface of the fifth digit, and similar branches to the fifth and fourth digits.

4. Musculo-Cutaneous Nerve, Plates 69, 70, and 71.—The cutaneous branch (sometimes two) of this nerve enters upon the dorsum of the foot, at the middle of the ankle. It breaks up into branches: the dorsal collateral digital nerves of the

fourth and third, the third and second digits, and that of the inner lateral digital surface of the pollex digit (Plate 70). It anastomoses with the external saphenous and the anterior tibial nerves.

5. Anterior Tibial Nerve, Plates 69 and 71.—The terminal portion of this nerve perforates the fascia at the middle of the first intermetatarsal space; it divides into the dorsal collateral digital nerves of the second and first digits.

6. Internal Saphenous Nerve, Plate 70.—This cutaneous nerve accompanies the vein of the same name, distributing to the skin of the inner border of the tarsal region.

7. Internal Calcaneal Nerve.—This nerve, branch of the posterior tibial, perforates the fascia to distribute to the skin of the inner side of the heel.

DISSECTION.—Untie the great toes. Make the skin incisions 5 and 6, of Figure 5 (page 123), and reflect flaps well off the antero-inner and outer lateral areas of the leg. Expose the subcutaneous veins and nerves.

8. Internal Saphenous Vein.—This subcutaneous vein may be followed, in its proximal course along the inner surface of the leg to the inner side of the knee, where it was before described (page 114; Plate 63). It receives tributary branches from the anterior and posterior surfaces of the leg.

9. Internal Saphenous Nerve.—This nerve accompanies the last-described vein; it has a distal course from where it enters the proximal limit of this dissection. It distributes patellar and other branches to the anterior and posterior (Plate 84) surfaces of the leg.

10. Musculo-Cutaneous Nerve, Plate 69.—The cutaneous branch (sometimes two) of this nerve, pierces the fascia of the leg, at a variable point, in the distal half of its outer antero-lateral area, continuing therefrom to the foot (page 124).

11. Cutaneous Branches of the External Popliteal Nerve.—Branches of this nerve distribute in the proximal half of the outer antero-lateral area of the leg.

12. Fascia of the Leg and Foot, Plates 69 and 70; Figs. 2 and 3, Plate 3.—The fascia of the dissection area is attached to

the anterior border of the tibia and the anterior surface of the fibula (Plate 72); it isolates the muscles, which are lodged in the anterior tibio-fibular interosseous space (Plate 3). A special fascia, at the outer surface, isolates the peroneus longus and brevis muscles (Plate 3). At the ankle it forms the anterior annular ligament, from the distal border of which it is continued upon the dorsum of the foot; it is continuous at the borders of the foot with the plantar fascia (Plate 76).

DISSECTION.—Cut away the subcutaneous veins and nerves from the dorsum of the foot. Incise the fascia, longitudinally, upon the several tendons, and discover their synovial sheaths, by introducing probes into them (as with the palmar tendons in Fig. 2, Plate 4). Remove the fascia from the dorsum of the foot, clearing the tendons and defining the distal border of the anterior annular ligament.

13. Tendons upon the Dorsum of the Foot, Plates 71 and 72.—Between the malleoli four tendons enter from the leg upon the dorsum of the foot. They are from the inner to the outer side: that of the tibialis anticus, the extensor proprius pollicis, the extensor longus digitorum (initial tendon), and the peroneus tertius muscles. The initial tendon of the extensor longus digitorum gives off four terminal tendons, which have a longitudinal course to the digits, second to fifth, inclusive.

DISSECTION.—Clear away the subcutaneous veins and nerves from the fascia of the outer antero-lateral area of the leg; incise the fascia along the outer side of the anterior border of the tibia, and reflect the same to the outer side of the leg, as far as its fibular attachment (Plate 72). Allow the fascia to remain upon the proximal portion of the tibialis anticus muscle (Plate 72). Preserve that portion of the fascia, which forms the anterior annular ligament, by defining its proximal border.

14. Anterior Annular Ligament.—This is a dense portion of the fascia, opposite the anterior surface of the distal ends of the tibia and fibula; it is attached to the internal malleolus to the external malleolus and the dorsum of the distal portion of the calcaneum. It binds in place the outer antero-lateral muscles of the leg, as they pass to the dorsum of the foot. A loop of the ligament isolates the tendons of the extensor longus digitorum (initial) and the peroneus tertius muscles.

15. Tibialis Anticus Muscle, Plates 67, 71, and 72.—This is attached to the proximal two-thirds of the outer surface of

the shaft of the tibia ; its tendon commences at the distal third of the leg, passing upon the outer surface of the distal end of the tibia. It is included in a special compartment of the anterior annular ligament, posteriorly to which it enters upon the inner side of the dorsum of the foot, where it is continued into the plantar plane of the foot, at the distal third of the tarsal region.

16. Extensor Longus Digitorum Muscle, Fig. 1, Plate 67 ; Plates 68, 71, and 72.—This muscle is attached to the proximal three-fourths of the inner surface of the fibula ; its initial tendon passes posteriorly to the anterior annular ligament ; upon the dorsum of the tarsal region it divides into four terminal tendons, which pass to be attached to the dorsal surfaces of the bases of the phalangines and phalangettes of the digits, second to fourth, inclusive. The latter attachments will be dissected later (page 150 ; Figs. 2 and 3, Plate 82).

17. Peroneus Tertius Muscle.—This muscle has its proximal attachment to the distal portion of the inner surface of the fibula (it seems like a continuation of the last-described muscle) : its tendon passes posteriorly to the anterior annular ligament, to the outer side of the outer terminal tendon of the extensor longus digitorum. It has a distal course, along the outer side of the tarsal region, to its distal attachment to the dorsal surface of the fifth metatarsal bone.

18. Extensor Proprius Pollicis Muscle.—This muscle has its proximal attachment to the middle of the inner side of the fibula ; at the distal third of the leg it emerges from between the tibialis anticus and the extensor longus digitorum muscles. Its tendon passes, posteriorly to the anterior annular ligament, to the dorsum of the foot ; it then has a distal course—upon the astragalus, the scaphoid, the internal cuneiform, the first metatarsal, and the phalanx of the first digit—to its distal attachment at the dorsal surface of the base of the phalangette of the first or pollex digit.

DISSECTION.—Expose the pollex tendon of the extensor brevis digitorum muscle, the dorsalis pedis artery and veins, and the anterior tibial nerve, as lodged in the inner intertendinous space—between the tendon of the extensor

proprius pollicis muscle and the inner terminal tendon of the extensor longus digitorum muscle—upon the dorsum of the tarsal and metatarsal regions.

19. Pollex Tendon of the Extensor Brevis Digitorum Muscle, Plates 71 and 72.—This, the inner tendon of the muscle, has a distal, and oblique, course from the second digit (terminal) tendon of the extensor longus digitorum muscle, to its attachment to the dorsal surface of the base of the phalanx of the first digit.

20. Dorsalis Pedis Artery, Plates 71 to 74, inclusive.—This artery (venæ comites) enters upon the dorsum of the foot, from the posterior of the anterior annular ligament; it continues along the outer side of the tendon of the extensor proprius pollicis muscle, to where it bifurcates into the metatarsal and the second dorsal digital arteries. The *second dorsal digital artery* has a distal course, between the first and second metatarsal bones, giving off the first dorsal digital artery, to the inner lateral digital surface of the first digit; it is crossed upon its dorsal surface by the pollex tendon of the extensor brevis digitorum muscle.

21. Anterior Tibial Nerve.—This nerve is continued from the leg, to the dorsum of the foot, accompanying the dorsalis pedis artery, along its outer side. It gives off a branch from its outer side, which passes beneath the extensor brevis digitorum muscle. The nerve-trunk continues into the first intermetatarsal space, receives an anastomotic branch from the musculo-cutaneous nerve (Plate 69), and distributes as before described (page 125).

DISSECTION.—Incise and remove the fascia from the peroneus longus and peroneus brevis muscles, upon the outer or fibular surface of the leg. Trace their tendons posteriorly, and inferiorly, to the external malleolus and along the outer border of the foot.

22. Peroneus Longus Muscle, Fig. 2, Plate 67; Plates 71 to 74, inclusive.—This, the superficial muscle at the outer surface of the leg, is attached to the proximal half of the fibula. About the middle of the leg its tendon commences and continues upon the peroneus brevis muscle to the posterior of the external malleolus; it then winds inferiorly to the malleolus, where it is lodged in the inferior groove upon the outer surface

of the calcaneum. It runs along the outer border of the tarsal region, to where it passes into the plantar region, into a groove in the cuboid bone.

23. Peroneus Brevis Muscle, Plates 67, 68, and 71 to 74, inclusive.—This muscle is attached to the distal half of the outer surface of the fibula, where it is lodged beneath the last-described muscle. Its tendon commences posteriorly to the external malleolus, inferiorly to which it winds to the outer side of the tarsal region, where it is lodged in the superior groove upon the outer surface of the calcaneum, and is continued to its distal attachment to the base of the fifth metatarsal bone. The two grooves upon the outer surface of the calcaneum, for the tendons of the peroneus longus and brevis muscles, are separated by the peroneal tubercle (Plate 101).

DISSECTION.—Section the tendons of the extensor longus digitorum and the peroneus tertius muscles (Plate 72), and reflect their distal portions. Do not dissect the extensor tendons from the dorsal surfaces of the digits, but leave them to be worked and studied at page 149. Clear the surface of the extensor brevis digitorum muscle.

24. Extensor Brevis Digitorum Muscle, Plates 68, 71, 72, and 73.—This muscle is located upon the dorsum of the foot. Its proximal attachment is to the dorsal surface of the distal end of the calcaneum, where the muscle forms a point; it then expands into a flat muscle, whose distal limit projects four tendons to the dorsal surfaces of the digits, first to fourth, inclusive (described page 150; illustrated Figs. 2 and 3, Plate 82). The pollex tendon was before described (page 128).

DISSECTION.—Cut the tendon of the extensor proprius pollicis muscle (Plate 72). Reflect the proximal portions of the extensor longus digitorum, the peroneus tertius, and the extensor proprius pollicis muscles to the outer side; also, the tibialis anticus muscle to the inner side (Plate 73). Expose the anterior tibial vessels and nerve between the reflected muscles; trace the artery and nerve, and note their muscle branches.

25. Anterior Tibial Artery, Plate 73.—This artery (venæ comites) lies between the tibialis anticus muscle, to its inner side, and the peroneus tertius, extensor proprius pollicis, and extensor longus digitorum muscles, to its outer side. It affords

muscle branches to the contiguous muscles, gives off at the ankle-joint the external and internal malleolar branches, and is continued to the foot as the dorsalis pedis artery (page 128). It is lodged upon the anterior surface of the tibio-fibular interosseous ligament.

26. Anterior Tibial Nerve.—This nerve joins the last-described artery in the proximal third of the interosseous space; at first it lies to its outer side, then crosses to its inner side. It affords branches to the tibialis anticus, the extensor proprius pollicis, the extensor longus digitorum, and the peroneus tertius muscles (the latter descending in the substance of the extensor longus digitorum muscle).

DISSECTION.—Section the extensor brevis digitorum muscle (Plate 73); reflect its proximal portion to its attachment, at which it may be cut; turn off its tendons to the toes and cut them (do not dissect them at the dorsal surfaces of the digits, second to fourth, inclusive). Find the nerve and artery supplying the muscle—they enter its deep surface. Trace the branches of the dorsalis pedis artery; the dorsal digital, the dorsal collateral digital, and the perforating arteries.

27. Branches of the Dorsalis Pedis Artery, Plate 74.—These are the tarsal, and the branches of bifurcation—the metatarsal and the second dorsal digital. The *tarsal* crosses to the outer side of the tarsal region, supplying the extensor brevis digitorum muscle and the tarsal joints, and anastomosing with the external malleolar, of the anterior tibial, and the metatarsal. The *metatarsal* crosses, to the outer side of the tarsal region, upon the dorsal surface of the bases of the metatarsal bones—second, third, and fourth; it anastomoses as just stated.

28. Dorsal Digital Arteries, Plates 71 and 74.—These are six arteries (venæ comites), as follows: the *first* is a branch of the second, which runs upon the dorsal surface, and along the inner side of the distal portion, of the first metatarsal bone; the *second* is one of the branches of bifurcation of the dorsalis pedis, and is lodged in the first intermetatarsal space (page 128); the *third*, *fourth*, and *fifth* are distal branches from the metatarsal, having a distal course in the second, third, and fourth intermetatarsal spaces; the

sixth is a branch of the fifth, and runs along the outer side of the fifth metatarsal bone.

29. Dorsal Collateral Digital Arteries, Plates 71 and 74.—These ten arteries are branches of bifurcation or the continuation of the dorsal digital arteries: the first and tenth are the continuations of the first and sixth digital arteries, respectively; the second to ninth, inclusive, arise from the terminal bifurcations of the digital arteries, second to fifth, inclusive. They ramify in the dorsal halves of the lateral digital surfaces of the digits, as shown upon the second digit in Plate 71.

30. Perforating Arteries, Plates 68 and 74; Fig. 1, Plate 82.—These four arteries (*venæ comites*) perforate from the plantar region, between the proximal ends of the dorsal interossei muscles, to anastomose with the dorsal digital arteries, second to fifth, inclusive. The first (the *communicating* branch of the anterior tibial, of authors) anastomoses with the second dorsal digital; the second, third, and fourth are branches from the plantar digital arteries (page 148).

31. Dorsal Interossei Muscles, Plates 68 and 74.—The dorsal surfaces of these four muscles appear in the intermetatarsal spaces, first to fourth, inclusive.

DISSECTION.—Cut away the extensor longus digitorum, the peroneus tertius, and the extensor proprius pollicis muscles from their fibular attachments; preserve the attachment of the fascia and intermuscular septum to the fibula, at the outer side of these muscles. Trace the musculo-cutaneous nerve between the peroneus longus and brevis muscles (Plate 74). Cut the peroneus longus muscle, at the head of the fibula, as required in tracking the musculo-cutaneous nerve to its origin from the external popliteal nerve (Plate 74); follow the branches of the musculo-cutaneous nerve to the peroneus longus and brevis muscles. Trace the anterior tibial nerve through the proximal portions of the extensor longus digitorum and the peroneus longus muscles, to its origin from the external popliteal nerve.

32. External Popliteal Nerve, Plates 72 and 74.—This nerve winds around the head or proximal end of the fibula, from the popliteal space. It enters the proximal portion of the peroneus longus muscle, where it gives off the recurrent articular branch, and bifurcates into the musculo-cutaneous and the anterior tibial nerves.

33. Musculo-Cutaneous Nerve, Plate 74.—This nerve, given off from the external popliteal, has a muscle distribution to the peroneus longus and brevis muscles; and a cutaneous distribution as before described (pages 124 and 125) and illustrated (Plates 69 and 70).

34. Anterior Tibial Nerve.—This nerve passes from the external popliteal, through the proximal portions of the peroneus longus muscle, the intermuscular septum, and the extensor longus digitorum muscle, to reach the anterior surface of the tibio-fibular interosseous ligament, where it was before described (page 130).

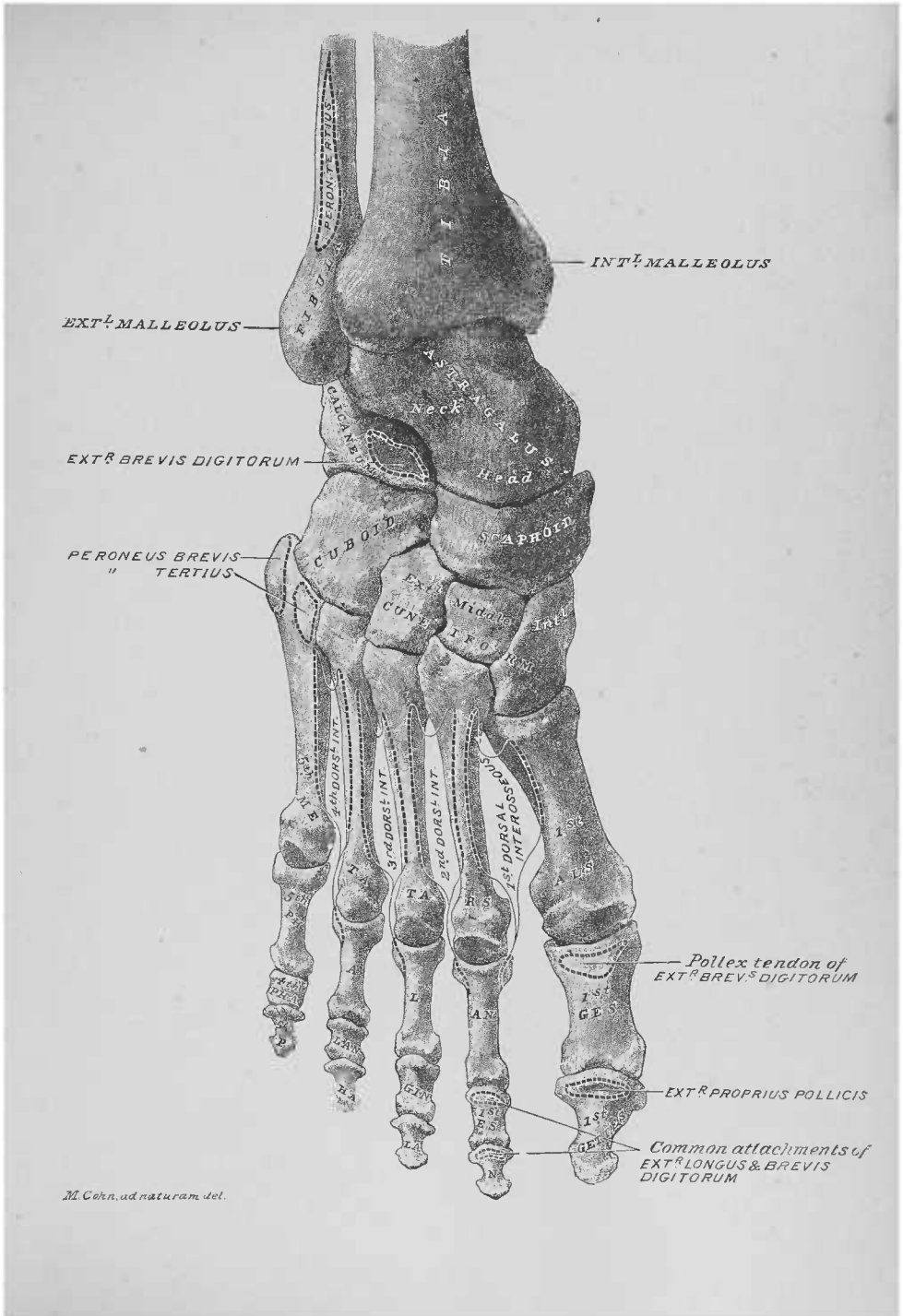
DISSECTION.—Trace the anterior tibial artery to its proximal limit; follow its anterior tibial recurrent branch. Find, at the opening in the distal portion of the tibio-fibular interosseous ligament, the anterior peroneal artery; follow it to its anastomosis.

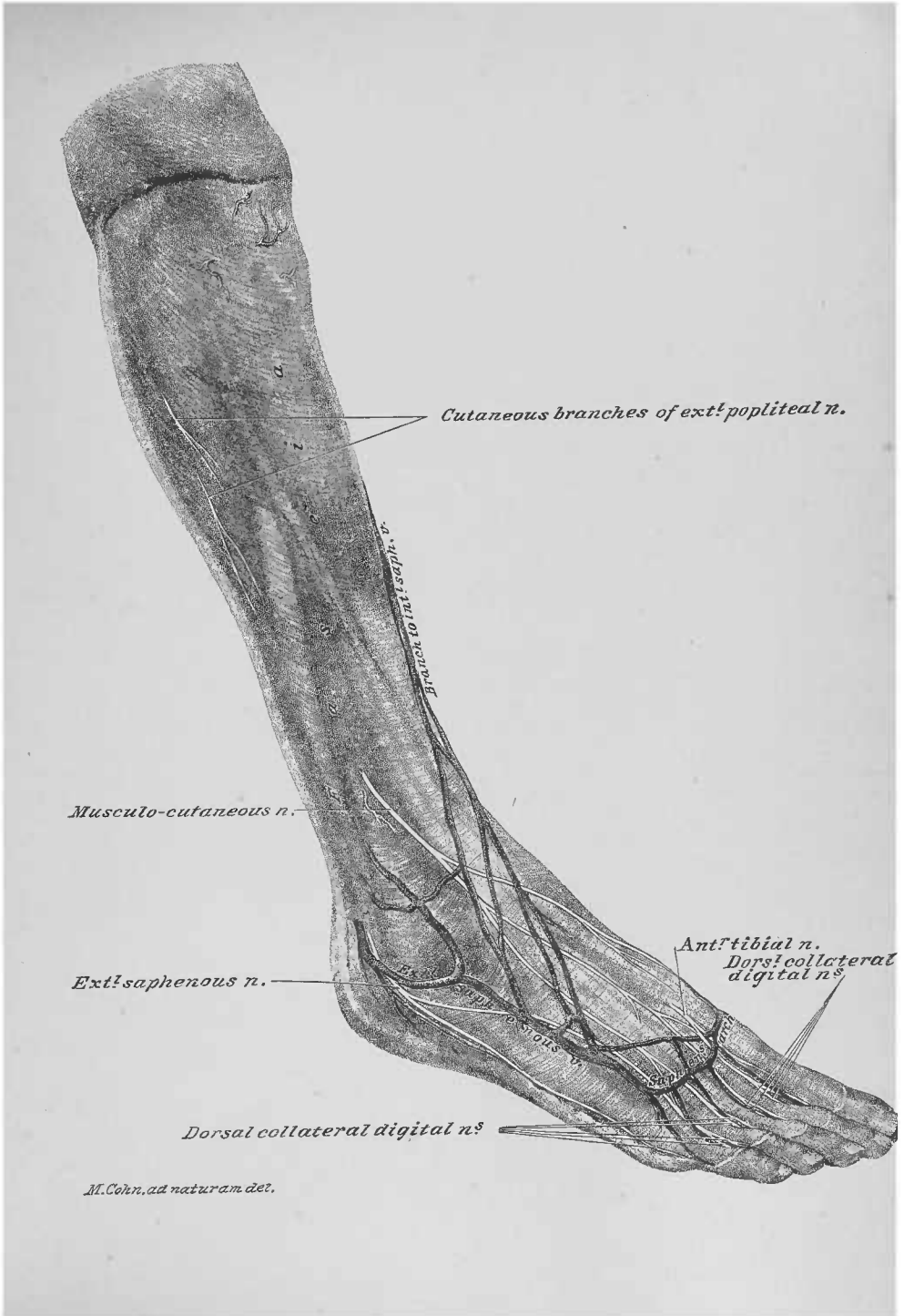
35. Anterior Tibial Artery.—The proximal end of this artery (venæ comites) emerges, from the posterior to the anterior region of the leg, by a deficiency in the proximal portion of the tibio-fibular interosseous ligament.

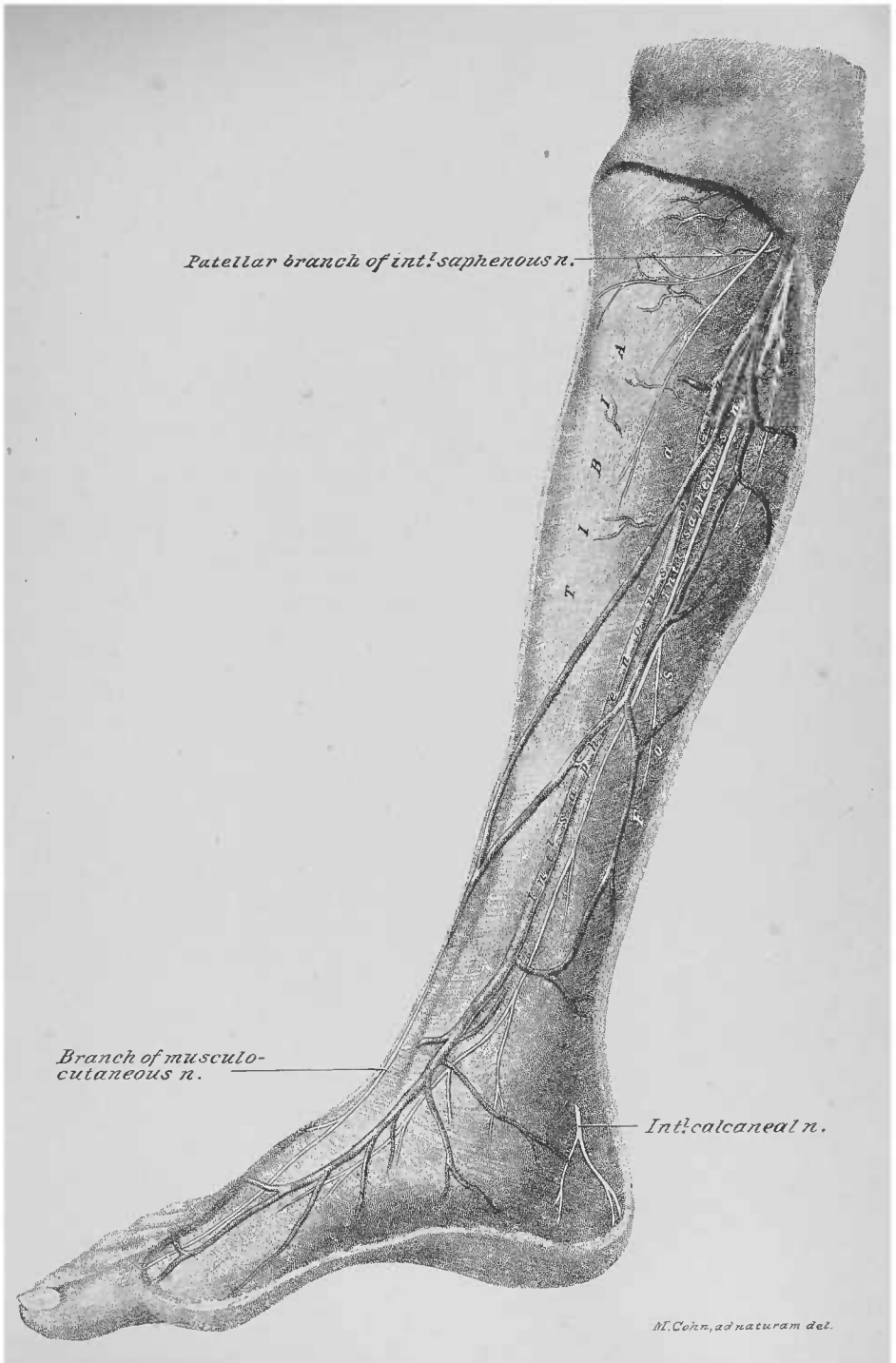
36. Anterior Tibial Recurrent Artery.—This artery (venæ comites) is given off from the proximal end of the anterior tibial; it has a recurrent course through the proximal portion of the extensor longus digitorum muscle, to contribute to the peri-articular network of anastomosing arteries upon the outer antero-lateral area of the knee.

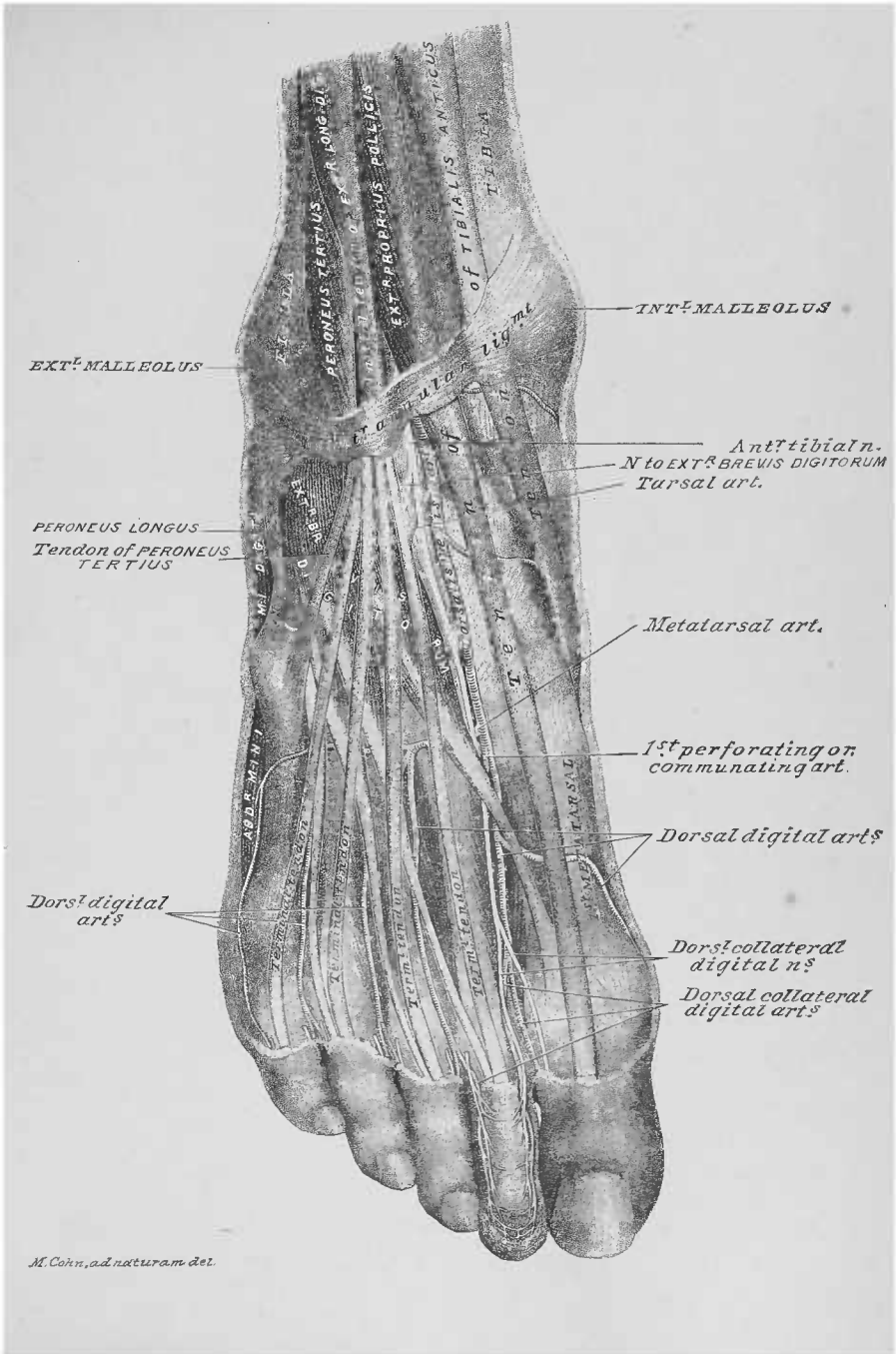
37. Anterior Peroneal Artery.—This artery (venæ comites), branch of the peroneal artery of the posterior region of the leg, emerges, to the anterior of the leg, by an opening in the distal portion of the tibio-fibular interosseous ligament. It takes a distal course along the outer side of the ankle-joint, to the tarsal region of the foot, where it anastomoses with the external malleolar branch of the anterior tibial artery.

DISSECTION.—After this dissection, be careful to keep the leg and foot wet; more especially the toes, dorsum of the foot, ankle, and knee.









Ext: popliteal
n.

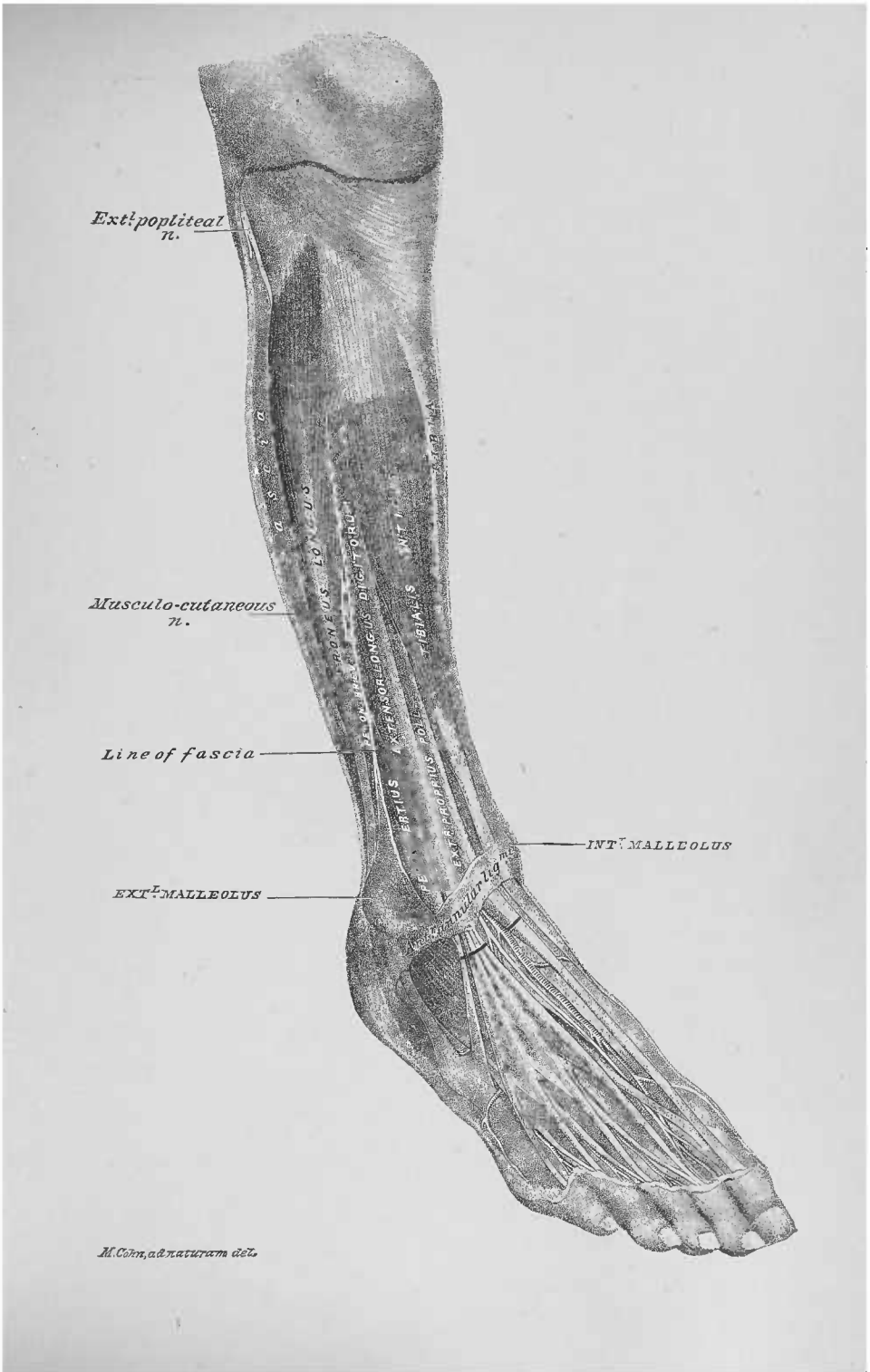
Musculo-cutaneous
n.

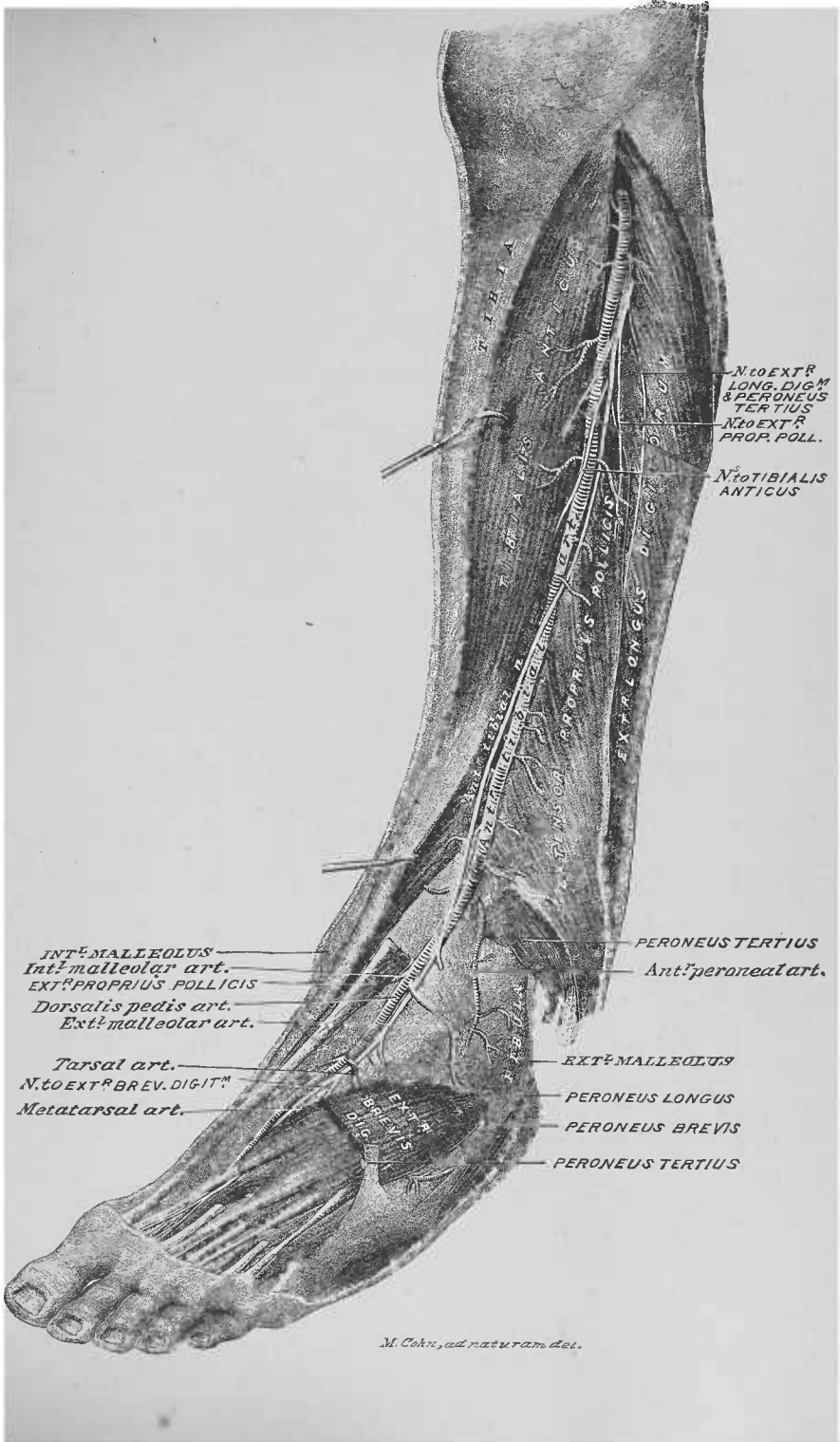
Line of fascia

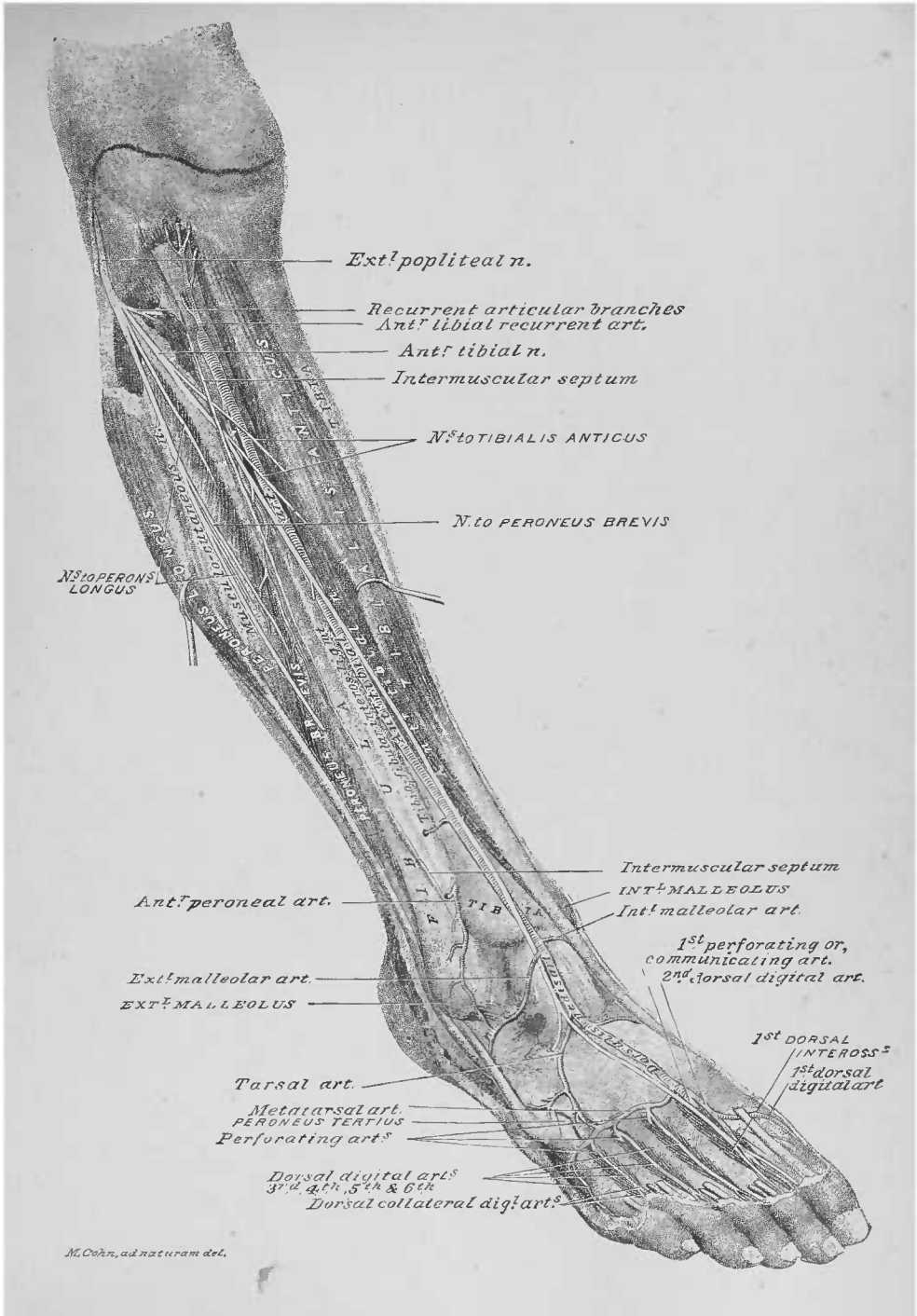
EXT^L MALLEOLUS

INT^R MALLEOLUS

M. Cohn, ad naturam del.







ELEVENTH DISSECTION.

PLANTAR REGION OF THE FOOT.

DISSECTION.—Raise the foot and lodge the heel on a block, so as to bring the sole on a convenient level for the dissector standing in front of it. Steady the foot by chain-hooks or strings.

Terms of Relation.—The special terms *proximal* (toward the heel), *distal* (from the heel), *outer side*, *inner side*, *plantar surface*, and *dorsal surface* will apply to the entire area of the dissection; *pollex border* and *minim border* to the tarsal and metatarsal regions; *plantar* and *lateral digital surfaces* to the digits.

Bone Areas, Plate 75.—The plantar surface of the following bones forms the osseous plane of the sole of the foot: the calcaneum; the astragalus; the cuboid; the scaphoid; the three cuneiform—internal, middle, and external; the five metatarsal; the fourteen bones of the digits—five phalanges, four phalanges, and five phalangettes (see page 123). With the exception of the astragalus and the middle cuneiform, they all afford attachments to muscles.

DISSECTION.—Make the skin incisions 1, 2, and 3 of Figure 6, and reflect flaps as indicated. Where the dorsum of the foot has been previously dissected the flaps will have to be cut away; otherwise they can be tied over the dorsum of the foot by strings.

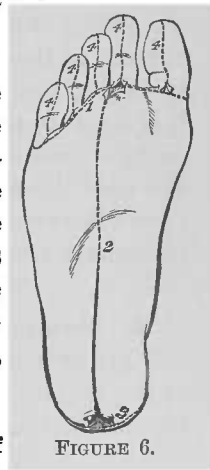


FIGURE 6.

1. Subcutaneous Tissue.—This plane of tissue is thick and dense over the heel and outer half of the dissection area, with

large areolæ for the lodgement of fat ; over the inner half it is thinner, especially at the hollow of the sole of the foot.

DISSECTION.—Remove the subcutaneous tissue from the plantar fascia, being careful to preserve the vessels and nerves superficial to it. Determine the portions of the plantar fascia and the distal slips of its middle portion. Make the skin incisions 4, 4, 4, 4, 4, of Figure 6, and reflect flaps from the respective plantar and lateral digital surfaces of the digits ; expose the plantar collateral digital nerves and vessels, and the sheaths of the flexor tendons.

2. Plantar Fascia, Plate 76.—This fascia is a thick plane of fibrous tissue, which stretches from the heel to the toes. It consists of three portions : the middle, the inner, and the outer. The *middle portion*, the thickest of the three, has a proximal attachment to the calcaneum ; in the metatarsal region it spreads laterally and divides into five slips, which pass to the sheaths of the flexor tendons—on the digits—and to the sides of the heads of the metatarsal bones ; at the distal ends of the slips, transverse fibres bridge across the foot from one to the other—the *superficial transverse ligament*. The *inner portion* has a proximal attachment to the calcaneum and along the inner border of the middle portion of the fascia ; it spreads to the pollex border of the foot, where it is continued to the dorsal surface of the same. The *outer portion* is attached to the calcaneum and the outer border of the middle portion of the fascia ; it spreads to the minim border of the foot, where it is continued to the dorsal surface of the same. At the junctions of the middle with the respective inner and outer portions septa are projected between the muscles, which determine three longitudinal compartments, for muscles, etc.

3. Cutaneous Arteries and Nerves.—Small plantar cutaneous arteries and nerves perforate to the subcutaneous plane of the region, along the borders of the middle portion of the plantar fascia.

4. First Digital Nerve, Plates 76 and 77.—This nerve, branch of the internal plantar, perforates the fascia near the pollex border of the foot, opposite the first metatarsal bone ; it continues as the inner plantar collateral digital nerve of the pollex digit.

5. Sixth Digital Artery.—This artery (venæ comites), branch of the fifth digital, crosses opposite the inner half of the head of the first metatarsal bone, to become the inner plantar collateral digital artery of the pollex digit.

6. Internal Plantar Artery.—The terminal portion of this artery (venæ comites) perforates the inner portion of the plantar fascia to the outer side of, and a little distal to, the point of perforation of the first digital nerve; it accompanies the nerve, along its outer side, and anastomoses with the sixth digital artery.

7. First Digital Artery and Its Anastomotic Branch.—This artery (venæ comites), branch of the external plantar, perforates the outer portion of the plantar fascia, near the outer border of the middle portion of the plantar fascia. It gives off an anastomotic branch to the second digital artery. The first digital artery is continued to the fifth digit, as its outer plantar collateral digital artery.

8. Sixth Digital Nerve.—This nerve perforates the fascia near the point where the first digital artery emerges. It accompanies the artery, along its inner side, becoming the outer plantar collateral digital nerve of the fifth digit.

9. Second, Third, Fourth, and Fifth Digital Nerves.—These four nerves present, for a portion of their course, in the metatarsal region, between the slips of the middle portion of the plantar fascia.

10. Branches of the Anastomotic Artery from the Internal Plantar Artery.—These arteries (venæ comites) are seen, for a part of their course, at the inner sides of the slips of the middle portion of the plantar fascia, accompanying the portions of the digital nerves there lodged.

11. Plantar Collateral Digital Nerves.—These nerves emerge, from the dorsal surface of the superficial transverse ligament, into the subcutaneous tissue of the lateral digital surfaces.

12. Plantar Collateral Digital Arteries, Plates 76 and 77.—These arteries (venæ comites) appear in the subcutaneous

tissue of the webbing between the digits ; they have a distal course in the subcutaneous tissue of the lateral digital surfaces, upon the dorsal surface of the last-described nerves.

13. Digital Sheath of the Flexor Tendons, Plate 76.—A fibrous sheath invests the flexor tendons, upon the plantar surface of each digit ; it is attached to the lateral borders of the phalanx and the phalangeine, and to the plantar surface of the phalangette of the digit. Its longitudinal fibres are continued from the plantar fascia. Opposite the flexures of the joints its texture is so modified as to allow flexion and extension of the digit. The plantar collateral digital vessels and nerves lie superficial to it.

DISSECTION.—Make a transverse incision through the middle portion of the plantar fascia (Plate 76), and reflect its distal portion with the superficial transverse ligament ; preserve the digital nerves and the branches of the anastomotic artery, from the internal plantar artery, between the slips of the fascia. Reflect its proximal portion, and note the existence of an intermuscular septum at its outer and another at its inner limit ; also, that it is attached to the subjacent flexor brevis digitorum muscle, from which it should not be removed (Plate 77). Trace the digital branches of the internal plantar nerve ; also their muscle branches. Follow the distribution of the anastomotic branch of the internal plantar artery. Slit up the sheaths of the flexor tendons and clear the plantar plane of the flexor brevis digitorum muscle.

14. Digital Branches of the Internal Plantar Nerve, Plate 77.—The internal plantar nerve emerges at the distal angle of divergence of the flexor brevis digitorum and the abductor pollicis muscles. The first digital nerve is given off from its inner side ; it was before described in the distal part of its course (page 134). The second and third come off as one trunk, which bifurcates into the two nerves. The fourth is the terminal portion of the internal plantar nerve. The second, third, and fourth digital nerves have a distal course to where they bifurcate, respectively, into the plantar collateral digital nerves of the first and second, second and third, and third and fourth digits.

15. Nerves to the Flexor Brevis Pollicis Muscle.—The first digital nerve, near its proximal end, supplies a branch to the inner head of this muscle ; the outer head receives a branch from the internal plantar nerve, before the giving off of the second and third digital nerves.

16. Nerves to the First and Second Lumbricales Muscles.—The first lumbricalis muscle is supplied by the third digital nerve; the second lumbricalis receives its nerve from the fourth digital nerve.

17. Anastomotic Branch of the Internal Plantar Artery.—This artery (*venæ comites*), branch of the internal plantar, emerges from the inner intermuscular septum, to the plantar surface of the flexor brevis digitorum muscle; it takes a distal course, breaking up into three branches, which accompany—lying in a deeper plane—the second, third, and fourth digital nerves, before referred to (page 135). The branches anastomose, respectively, with the fifth, fourth, and third digital arteries.

18. Flexor Brevis Digitorum Muscle, Plates 75, 77, and 78.—This muscle occupies the middle of the plantar area: its proximal attachment is to the calcaneum and the dorsal surface of the proximal third of the middle portion of the plantar fascia; in the metatarsal region it projects four tendons to the digits, second to fifth, inclusive; opposite the phalanx of a digit the tendon splits and reunites again, thereby forming a button-hole opening for the transit of a terminal tendon of the flexor longus digitorum muscle; after having provided this point of transit of a longus tendon, the brevis tendon splits again for attachment to the borders of the plantar surface of the phalange of a digit.

DISSECTION.—Dissect off the inner portion of the plantar fascia. Preserve the first digital nerve and the sixth digital artery (pages 134 and 135). Follow the internal plantar artery in a proximal direction to where it emerges from a deeper plane. Clear the surface of the abductor pollicis muscle.

19. Internal Plantar Artery, Plate 77.—The terminal portion of this artery (*venæ comites*) emerges, from a deep plane, in the angle of divergence of the flexor brevis digitorum and the abductor pollicis muscles. It accompanies, along its outer side, the first digital nerve; at its distal end it anastomoses with the sixth digital artery. It runs along the plantar surface of the outer head of the flexor brevis pollicis muscle.

20. Abductor Pollicis Muscle, Plates 77 and 78.—This muscle occupies the inner border of the tarsal and metatarsal

regions of the plantar area of the foot. Its proximal attachment is to the inner tuberosity of the calcaneum and to the plantar ligaments; in the metatarsal region it forms a tendon, which joins the inner head of the flexor brevis pollicis muscle; the two muscles have a common point of attachment to the inner side of the base of the phalanx of the pollex digit. In its course it covers the tendons of the tibialis posticus and anti-cus muscles.

DISSECTION.—Remove the outer portion of the plantar fascia; track, in a proximal direction beneath the fascia, the fifth and sixth digital nerves, and the first digital artery (Plate 77), to where they emerge from a deeper plane. Clear the plantar surface of the abductor minimi digiti muscle.

21. Fifth and Sixth Digital Nerves, Plate 77.—These nerves, branches of the superficial branch of the external plantar nerve, appear in the distal angle of divergence of the flexor brevis digitorum and the abductor minimi digiti muscles: the fifth digital nerve bifurcates into the plantar collateral digital nerves to the fourth and fifth digits; the sixth digital nerve has been before described (page 135).

22. First Digital Artery.—This artery (venæ comites), branch of the external plantar, accompanies the sixth digital nerve, lying to its outer side; its distal portion has already been described (page 135). Its anastomotic branch to the second digital artery passes to the dorsal surface of the minim flexor tendons.

23. Abductor Minimi Digiti Muscle, Plates 75, 77, and 78.—This muscle extends along the minim border of the foot; its proximal attachment is to the calcaneum, and to the plantar ligaments; its distal attachment is to the outer side of the proximal end of the shaft of the phalanx of the fifth digit.

DISSECTION.—Cut away the sheaths of the flexor tendons and expose the tendon of the flexor longus pollicis muscle, and the digital ends of the terminal tendons of the flexor longus digitorum muscle. Clear the surfaces of the exposed areas of the flexor brevis pollicis, the lumbricales, and the flexor brevis minimi digiti muscles. Determine the distal portions of the second, third, fourth, and fifth digital arteries.

24. Tendon of the Flexor Longus Pollicis Muscle, Plates 77 and 78.—The tendon of this muscle emerges from the dorsal

surface of the inner border of the flexor brevis digitorum muscle, and runs through the pollex metatarsal (upon the plantar surface of the flexor brevis pollicis muscle) and digital areas.

25. Terminal Tendons of the Flexor Longus Digitorum Muscle.—The distal ends of these tendons appear on the plantar surfaces of the digits, second to fifth, inclusive, distal to the button-hole openings in the tendons of the flexor brevis digitorum muscle (page 137).

26. Flexor Brevis Pollicis Muscle.—The plantar surface of the first metatarsal bone lodges this muscle; the tendon of the longus pollicis muscle runs, on its plantar surface, in a furrow between its heads (Plate 81). Its inner head and a portion of its outer head appear at this stage of the dissection.

27. Digital Arteries, Plates 77 and 79.—The distal portions of the second, third, fourth, and fifth digital arteries appear to the outer sides of, and parallel with, the flexor tendons. They pass into the webbing between the toes, and there bifurcate into the plantar collateral digital arteries (page 135.)

DISSECTION.—Section (Plate 77) the proximal ends of the exposed portions of the first digital, the internal plantar, and the fifth and sixth digital nerves. Cut the nerves to the flexor brevis pollicis and those to the first and second lumbricales muscles. Reflect the digital nerves, first to sixth, inclusive, off from the toes. Section the proximal ends of the anastomotic artery from the internal plantar, the terminal portion of the internal plantar artery, and the first digital artery. Reflect the first digital artery (cutting its anastomotic branch) and the internal plantar artery over the toes; turn off the branches of the anastomotic artery from the internal plantar artery to the anastomoses of its branches with the digital arteries—third, fourth, and fifth—and cut them away. Section (Plate 78) the flexor brevis digitorum, the abductor pollicis and the abductor minimi digiti muscles; reflect their distal portions and cut them away (Plate 79); turn off their proximal portions, noting their artery and nerve supply; cut the nerves close to the muscles and then cut away the muscles near their calcaneal attachments (Plate 79). Follow to their proximal ends, at the inner side of the calcaneum, the internal plantar nerve and artery. Trace the external plantar artery in its distal course from the inner surface of the ankle. Follow the external plantar nerve in its distal course from the inner surface of the ankle, and determine its muscle branches; note that the distal ones cross upon the plantar surface of the external plantar artery.

28. Internal Plantar Artery, Plate 79.—This artery (venæ comites) arises, at its proximal end, from the bifurcation of the posterior tibial artery, at the inner side of the calcaneum.

The artery has a distal course, in the longitudinal axis of the pollex digit, through the inner intermuscular septum; it emerges for superficial distribution as already stated (page 137). Its proximal and deep portion supplies the flexor brevis digitorum and the abductor pollicis muscles, and gives off its anastomotic artery (page 137).

29. Internal Plantar Nerve.—This nerve accompanies the internal plantar artery, lying to its dorsal surface; its proximal portion supplies the flexor brevis digitorum and the abductor pollicis muscles. Its metatarsal and digital portions were before described (page 136).

30. Nerve to the Flexor Brevis Digitorum Muscle.—In reflecting the proximal portion of this muscle this nerve, branch from the outer side of the internal plantar nerve, appears entering its inner side.

31. Nerve to the Abductor Pollicis Muscle.—From the inner side of the internal plantar nerve a branch is given to this muscle, which enters its outer surface.

32. Nerve to the Abductor Minimi Digiti Muscle.—The external plantar nerve gives off, opposite the inner surface of the calcaneum, a branch to this muscle; it crosses the foot, on the plantar surface of the proximal end of the flexor accessorius muscle, to reach the deep surface of the proximal half of the muscle it supplies.

33. External Plantar Artery, Plates 79 and 81.—This artery (venæ comites) originates from the bifurcation of the posterior tibial artery, at the inner side of the calcaneum; it passes obliquely across the proximal third of the sole of the foot, upon the plantar surface of the flexor accessorius muscle, and enters the outer intermuscular septum; through which it runs, in the longitudinal line of the fourth digit. The plantar surface of the distal third of the artery is crossed by branches of the external plantar nerve. Opposite the base of the fourth metatarsal bone the artery curves to the inner side and passes to the dorsal surface of the outer border of the terminal tendon, to the fifth digit, of the flexor longus digitorum muscle. In the exposed portion of its course it gives off muscle branches and the first

digital artery; the latter has been described (page 135) and illustrated (Plates 76 and 77).

34. External Plantar Nerve.—This nerve appears in the sole of the foot parallel with, and to the inner side of, the external plantar artery; it crosses, as does the artery, to the minium half of the region. It bifurcates into a superficial and a deep branch: the *superficial branch* bifurcates, in turn, into the fifth and sixth digital nerves, before described (page 138); the *deep branch* follows the course of the external plantar artery, lying to its inner side, and passes with it into the metatarsal region. The trunk of the nerve and the exposed portion of its deep branch give off nerves to muscles of the tarsal and metatarsal regions.

35. Nerve to the Flexor Accessorius Muscle, Plates 79 and 81.—The external plantar nerve gives off a distal branch to this muscle as it crosses its plantar surface.

36. Muscle Branches from the Deep Branch of the External Plantar Nerve, Plate 79.—The deep branch of the external plantar nerve gives off the following distal branches from its outer side: the first, to the flexor brevis minimi digiti and the third plantar interosseous muscles; the second, to the fourth dorsal interosseous muscle; the third and fourth disappear in their distal course, beneath the minim terminal tendon of the flexor longus digitorum muscle. These nerves pass upon the plantar surface of the external plantar artery.

DISSECTION.—Clear the tendons at the pollex border of the tarsal region; the initial and terminal tendons of the flexor longus digitorum muscle; and the tendon of the flexor longus pollicis muscle. Expose the accessorius, the lumbricales, and the flexor brevis minimi digiti muscles; also portions of the transversus pedis, the adductor pollicis, the third plantar interosseous, the fourth dorsal interosseous, and the second plantar interosseous muscles. Determine the tendons at the minim border of the tarsal region.

37. Tendon of the Tibialis Posticus Muscle, Plates 75, 79, 80, and 81.—This tendon enters the pollex border of the tarsal region, distal to the internal malleolus, and continues to its attachment to the tubercle of the scaphoid bone.

38. Tendon of the Tibialis Anticus Muscle.—The proximal portion of this muscle occupies the anterior surface of the leg,

and was before described (page 127) and illustrated (Plates 67, and 71 to 74, inclusive); its distal tendon enters the pollex border of the plantar surface, from the dorsum of foot, to reach its distal attachment, at the plantar surfaces of the internal cuneiform bone and of the base of the first metatarsal bone.

39. Initial and Terminal Tendons of the Flexor Longus Digitorum Muscle.—The *initial tendon* of this muscle enters the plantar region, from the posterior surface of the leg, at a point distal to the internal malleolus of the ankle; it takes an oblique course therefrom to about the middle of the proximal limit of the metatarsal region, where it gives off *four terminal tendons* to the digits, second to fifth, inclusive; in the digital regions the terminal tendons pass through the button-hole openings in the tendons of the flexor brevis digitorum muscle (page 137; Plates 77 to 80, inclusive) to their distal attachments, to the plantar surfaces of the bases of the phalangettes of the digits, second to fifth, inclusive.

40. Tendon of the Flexor Longus Pollicis Muscle, Plates 75, and 77 to 81, inclusive.—This tendon enters the sole of the foot by a groove at the posterior border of the astragalus; it runs in a groove upon the sustentaculum tali of the calcaneum, to the outer side of the initial tendon of the flexor longus digitorum muscle. It takes a distal and straight course to the pollex digit, passing to the dorsal surface of the initial tendon of the flexor longus digitorum muscle; in the metatarsal region it lies between the heads of the flexor brevis pollicis muscle; it has its distal attachment to the plantar surface of the base of the phalangette of the pollex digit.

41. Flexor Accessorius Muscle, Plates 75, 79, and 80.—This muscle has two points of proximal attachment—an inner and an outer—upon the plantar surface of the calcaneum; they are united by fibrous tissue. The two portions unite into a flat muscle, which has its distal attachment to the outer border of the initial tendon of the flexor longus digitorum muscle, proximal to its division into its four terminal tendons.

42. Lumbricales Muscles, Plates 77 to 80, inclusive.—These muscles are lodged to the inner sides of the terminal tendons of the flexor longus digitorum muscle. Their proximal ends

are attached to the contiguous terminal tendons; their distal ends form tendons, which pass over the inner sides of the metatarso-phalangeal articulations, second to fifth, inclusive.

43. Flexor Brevis Minimi Digiti Muscle, Plates 75 and 77 to 81, inclusive.—This muscle occupies the plantar surface of the fifth metatarsal bone. Its proximal attachment is to the plantar surface of the base of the fifth metatarsal bone and the contiguous portion of the sheath of the peroneus longus muscle; it has a distal and slightly oblique course to its attachment, at the outer side of the base of the phalanx of the fifth digit.

44. Transversus Pedis Muscle, Plates 79 and 80.—Portions of the plantar surface of this muscle appear between the distal ends of the lumbricales muscles and the terminal tendons of the flexor longus digitorum muscle.

45. Adductor Pollicis Muscle, Plates 77 to 80, inclusive.—Between the first lumbricalis and the outer head of the flexor brevis pollicis muscles a small area of this muscle presents.

46. Interosseous Muscles, Plates 79 and 80.—Between the inner border of the flexor brevis minimi digiti muscle and the outer border of the minim terminal tendon of the flexor longus digitorum muscle portions of the third plantar, the fourth dorsal, and the second plantar interosseous muscles appear.

47. Tendons of the Peroneus Longus and Peroneus Brevis Muscles, Plates 79 and 80.—Along the inner border of the tarsal region these two tendons present: the longus tendon running in its sheath along the outer border of the flexor accessorius muscle; the brevis tendon along the outer border of the longus tendon.

DISSECTION.—Cut the proximal ends of the internal plantar artery and nerve (Plate 79), and dissect away their distal portions. Section the initial tendon of the flexor longus digitorum muscle, the tendon of the flexor longus pollicis muscle, and the flexor accessorius muscle (Plate 80); reflect the distal portions of the tendons over the toes, carrying the lumbricales muscles with the terminal digitorum tendons. Determine the slip of communication between the tendon of the flexor longus pollicis muscle and the distal portion of the initial tendon of the flexor longus digitorum muscle; after which the slip may be cut. In raising the fourth and third lumbricales muscles note the nerves that enter their dorsal surfaces; trace the nerves to the second plantar

interosseous and the transversus pedis nerves; the two latter nerves are in turn given off from the deep branch of the external plantar nerve. Find the nerves to the first plantar and the third dorsal interosseous muscles. Follow the deep branch of the external plantar nerve, and the external plantar artery, into the metatarsal region.

48. Tendinous Slip between the Tendon of the Flexor Longus Pollicis and the Initial Tendon of the Flexor Longus Digitorum Muscles.—At the crossing of these tendons (Plates 79 and 80) a tendinous slip passes from the pollicis to the digitorum tendon.

49. Nerve to the Fourth Lumbricalis Muscle, Plate 81, and Fig. 1, Plate 82.—In reflecting this muscle its nerve will be seen to enter its dorsal surface; the same may be traced to where it is given off from the nerve to the second plantar interosseous muscle.

50. Nerve to the Second Plantar Interosseous Muscle, Plates 79, 81, and Fig. 1, Plate 82.—This is the third nerve given off from the deep branch of the external plantar nerve.

51. Nerve to the Third Lumbricalis Muscle, Plate 81, and Fig. 1, Plate 82.—As the muscle is reflected this nerve is seen to enter its dorsal surface; it can be followed to its origin from the nerve to the transversus pedis muscle.

52. Nerve to the Transversus Pedis Muscle, and its Branches to the First Plantar and the Third Dorsal Interosseous Muscles.—The nerve to the transversus pedis muscle—from the deep branch of the external plantar—enters its proximal side. It gives a branch to either side: the inner to the first plantar interosseous muscle; the outer to the third dorsal interosseous muscle.

53. Deep Branch of the External Plantar Nerve, Plate 81.—After having given off the nerve to the transversus pedis muscle, this branch is continued, at the outer border of the adductor pollicis muscle, to the dorsal surface of the latter muscle.

54. External Plantar Artery.—This artery curves toward the inner side of the metatarsal region of the foot, accompanying the last-described nerve branch.

DISSECTION.—Expose the tarsal grooves for the tendon of the flexor longus pollicis muscle and the initial tendon of the flexor longus digitorum

muscle. Note the expansions of the tendon of the tibialis posticus muscle from the tubercle of the scaphoid bone.

55. Tarsal Grooves for the Long Flexor Tendons, Plates 75 and 81.—Between the tendon of the tibialis posticus and the inner border of the flexor accessorius muscle two longitudinal grooves present: the outer one upon the plantar surface of the sustentaculum tali of the calcaneum (Plate 75) for the tendon of the flexor longus pollicis muscle; the inner one for the initial tendon of the flexor longus digitorum muscle.

56. Expansions of the Tendon of the Tibialis Posticus Muscle, Fig. 1, Plate 82.—This tendon is not only attached to the tubercle of the scaphoid bone but it sends expansions across the area included by the tibialis anticus and the peroneus longus tendons, and the inner border of the flexor accessorius muscle.

DISSECTION.—Clean (Plate 81) the plantar surface of the transversus pedis muscle; determine the relations of the digital arteries to the slips of the muscle; and expose the adductor pollicis and the flexor brevis pollicis muscles.

57. Transversus Pedis Muscle, Plates 75, 79, 80, and 81.—This muscle crosses the plantar surfaces of the heads of the metatarsal bones, having a slip from the inner side of the head of each of those bones, from the fifth to the second, inclusive. These slips unite into a transverse muscle, which, at its inner end, has an attachment, in common with the adductor pollicis muscle and the outer head of the flexor brevis pollicis muscle, to the outer side of the plantar surface of the base of the phalanx of the pollex digit. Openings present between its slips and the plantar surfaces of the heads of the fourth, third, and second metatarsal bones.

58. Digital Arteries, Plates 77, 79, and 81.—The second, third, and fourth digital arteries lie upon the dorsal surface of the transversus pedis muscle; they emerge from the openings between the slips of that muscle and the heads of the metatarsal bones, into the webbing between the toes. The fifth digital artery emerges between the distal tendons of the flexor brevis pollicis muscle, gives off the sixth digital artery, and then continues to the webbing between the first and second toes, over the plantar surface of the outer portion of the compound flexor brevis pollicis tendon (page 147).

59. Adductor Pollicis Muscle, Plates 75, 81, and Fig. 1, Plate 82.—This muscle has its proximal attachment at the plantar surface of the bases of the third and fourth metatarsal bones and the contiguous portion of the sheath of the tendon of the peroneus longus muscle. It takes an oblique course to the outer surface of the base of the phalanx of the pollex digit, its fibres running parallel with those of the outer head of the flexor brevis pollicis muscle; it contributes to the compound flexor brevis pollicis tendon (page 147).

60. Flexor Brevis Pollicis Muscle, Plates 77 to 81, inclusive.—This muscle has an inner and an outer portion, or head, determined by the plantar surface of the muscle being furrowed (Plate 81), for the transit of the tendon of the flexor longus pollicis muscle (Plates 77 to 80, inclusive). The *inner portion* of the muscle has its proximal attachment to the expansion of the tendon of the tibialis posticus muscle (page 145); as it advances to its distal end it fuses with the tendon of the abductor pollicis muscle (page 137). The *outer portion* has its proximal attachment to the cuboid bone and the sheath of the tendon of the peroneus longus muscle. The two portions form a muscle upon the plantar surface of the first metatarsal bone; opposite the head of the bone, it divides into two distal tendons, which are united by fibrous tissue. The distal attachment of this muscle is by a compound tendon, which is described at page 147.

DISSECTION.—Section the nerve to the flexor brevis minimi digiti muscle (Plate 81); detach the proximal attachments of the muscle and reflect it to its distal end, where it may be cut (Fig. 1, Plate 82). Cut the slips of the transversus pedis muscle from their metatarsal attachments; note its nerve and cut it close to the muscle; turn off the muscle over the pollex digit. Cut the digital arteries (Plate 81) and clear the plantar collateral digital arteries from the lateral digital surfaces. Detach the proximal end of the adductor pollicis muscle; turn over its outer border so as to determine the entrance of its nerve at its dorsal surface; follow the nerve to its origin from the external plantar nerve, then cut it close to the muscle; continue the reflection of the muscle upon the pollex digit.

61. Nerve to the Adductor Pollicis Muscle, Fig. 1, Plate 82.—This nerve is given off from that portion of the deep branch of the external plantar nerve which is situated on the dorsal surface of the adductor pollicis muscle.

DISSECTION.—Cut the proximal attachments of the flexor brevis pollicis muscle and reflect it, in a distal direction, from the plantar surface of the first metatarsal bone and the fifth digital artery. Section the muscle into its two heads, through the furrow for the flexor longus pollicis muscle. Raise the fifth and sixth digital arteries and turn them upon the tarsus. Determine the *compound flexor brevis pollicis tendon* as formed by the heads of the flexor brevis pollicis muscle, the abductor pollicis, the adductor pollicis, and the transversus pedis muscles. Note the sesamoid bones included in the compound tendon; and, the ligament that attaches the proximal border of these bones to the plantar surface of the head of the first metatarsal bone.

62. Compound Flexor Brevis Pollicis Tendon, Plates 75, 81; Fig. 1, Plate 82.—The heads of the flexor brevis pollicis muscle have two distal tendons, which are united by fibrous tissue: the inner is joined by the tendon of the abductor pollicis muscle; the outer receives the adductor pollicis and the transversus pedis muscles. Each compound tendon contains a sesamoid bone; the two bones being lodged, respectively, upon the inner and outer tuberosities of the plantar surface of the head of the first metatarsal bone. To the distal side of the sesamoid bones the compound tendon is attached to the plantar and lateral digital surfaces of the base of the phalanx of the pollex digit. To the borders of the sesamoid bones is attached the plantar metatarso-phalangeal ligament (page 180).

DISSECTION.—Section the muscles near the sesamoid bones; cut the ligament from the latter to the first metatarsal bone, and turn the bones on end upon the base of the phalanx of the pollex digit (Fig. 1, Plate 82). Trace the terminal portion of the deep branch of the external plantar nerve.

63. Nerves to the Second and First Dorsal Interosseous Muscles, Fig. 1, Plate 82.—The terminal portion of the deep branch of the external plantar nerve lies upon the plantar surface of the interosseous muscles, where it bifurcates to supply the second and first dorsal interosseous muscles.

DISSECTION.—Trace the plantar arch through the metatarsal region and note its branches. Replace the fifth and sixth digital arteries.

64. Plantar Arch of the External Plantar Artery, Plate 82.—The plantar arch is formed by the deep branch of the external plantar artery; the artery curves as it enters the metatarsal region, opposite the base of the fourth metatarsal bone, and continues to the proximal end of the first intermetatarsal space,

where it anastomoses with the communicating artery from the bifurcation of the dorsalis pedis artery (page 128 ; Plate 74).

65. Digital Arteries, Fig. 1, Plate 82.—The first digital artery has been described (pages 135 and 138) ; the second, third, fourth, and fifth digital arteries are given off from the convexity of the plantar arch, having a distal course therefrom : the second, between the fourth dorsal and the second plantar interosseous muscles ; the third, between the third dorsal and the first plantar interosseous muscles ; the fourth, between the second and the first dorsal interosseous muscles ; the fifth, upon the outer side of the first metatarsal bone. The fifth digital artery gives off the sixth (page 145) ; the latter crosses, the plantar surface of the distal end of the inner head of the flexor brevis pollicis muscle, to the inner side of the pollex digit.

66. Perforating Branches of the Digital Arteries, Plate 74 and Fig. 1, Plate 82.—From the second, third, and fourth digital arteries perforating branches are given off, respectively, which pass to the dorsum of the foot, between the proximal ends of the attachments of the dorsal interosseous muscles (Plate 68). (These branches are at times given off from the plantar arch.)

DISSECTION.—Clear and determine the plantar surface of the plantar and dorsal interosseous muscles.

67. Plantar Interosseous Muscles, Plate 75 and Fig. 1, Plate 82.—These muscles, three in number, present at the plantar surface of the foot and are lodged to the outer sides of the second, third, and fourth intermetatarsal spaces. Their proximal attachments are to the inner sides of the third, fourth, and fifth metatarsal bones (Plate 75), respectively ; their distal ends form tendons, which wind, severally, over the inner sides of the third, fourth, and fifth metatarso-phalangeal joints.

68. Dorsal Interosseous Muscles, Plates 68, 74, and Fig. 1, Plate 82.—These four muscles occupy the four intermetatarsal spaces, appearing at both the dorsal and plantar surfaces of the foot. The first and second are to either side of the second metatarsal bone ; the third and fourth are to the outer sides of the third and fourth metatarsal bones, respectively. Their

proximal attachments are to the opposite dorsal-plane surfaces of the five metatarsal bones (Plate 68). Their distal ends form tendons, which cross the inner sides of the metatarso-phalangeal joints: the first over the inner side of that of the second digit; the second, third, and fourth over the outer sides of those of the second, third, and fourth digits.

DISSECTION.—Cut away the sesamoid bones and clean their surfaces. Replace the flexor longus pollicis and flexor longus digitorum tendons; suture their cut ends together. Extend the foot so as to see the dorsal and lateral digital surfaces of the toes. Recognize the distal attachments of the lumbricales muscles. Determine the double distal attachments of the dorsal and plantar interosseous muscles; also the construction of the compound digital extensor aponeuroses. The distal ends of the tendons of the extensor longus and brevis digitorum muscles were left, *in situ*, on the dorsal surface of the digits, second to fifth, inclusive (pages 129 and 130); they may now be dissected.

69. Sesamoid Bones, Fig. 1, Plate 82.—These are two oblong bones included in the compound flexor brevis pollicis tendon (page 147), with their dorsal surfaces articulating with the plantar surface of the head of the first metatarsal bone.

70. Lumbricales Muscles, Fig. 3, Plate 82.—The lumbricales muscles have their distal attachments to the inner sides of the bases of the phalanges of the digits, second to fifth, inclusive.

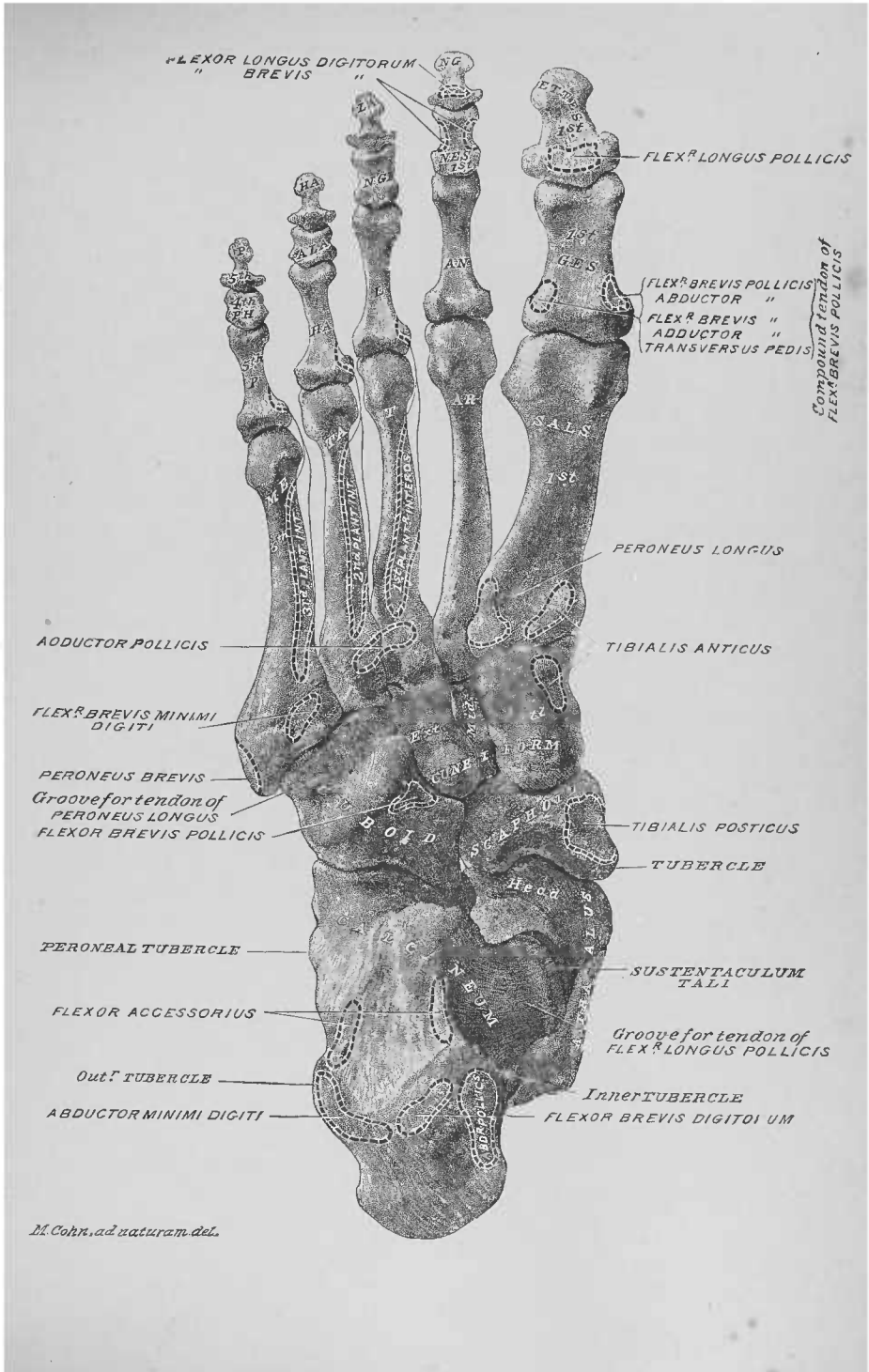
71. Distal Attachments of the Dorsal Interosseous Muscles, Fig. 2, Plate 82.—The distal tendon of each dorsal interosseous muscle may be determined to have two attachments: one to the lateral digital surface of the base of the phalanx of the digit to which it belongs (the first muscle to the inner side of the phalanx of the second digit; the second, third, and fourth muscles to the outer sides of the phalanges of the respective second, third, and fourth digits); another by a fibrous expansion, which contributes to the compound digital extensor aponeurosis of the digit.

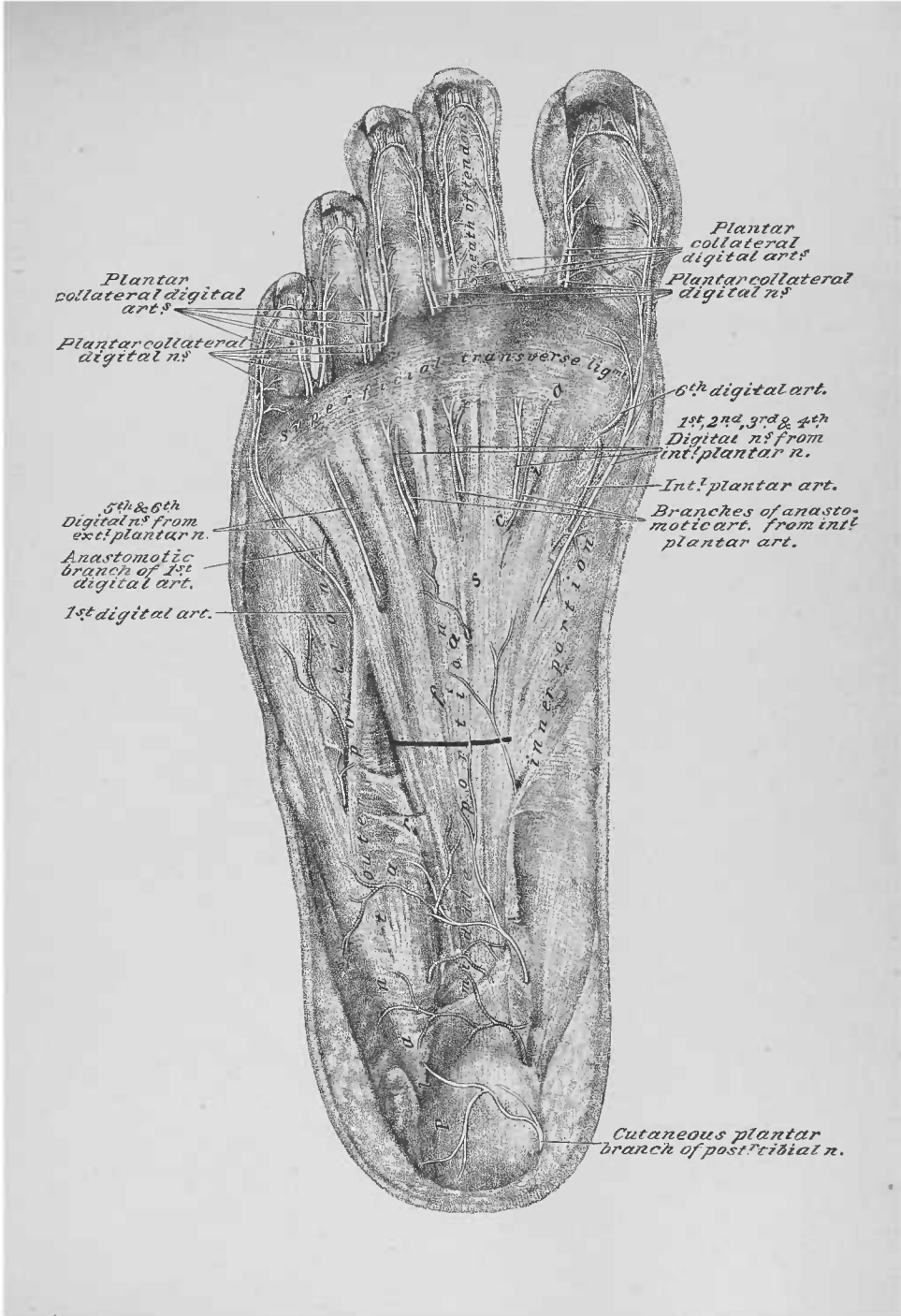
72. Distal Attachments of the Plantar Interosseous Muscles, Figs. 2 and 3, Plate 82.—The distal attachment of each of these muscles is also double: one to the inner surface of the base of the phalanx of the digit—third, fourth, and fifth; the other, by a fibrous expansion, to the inner borders of the terminal

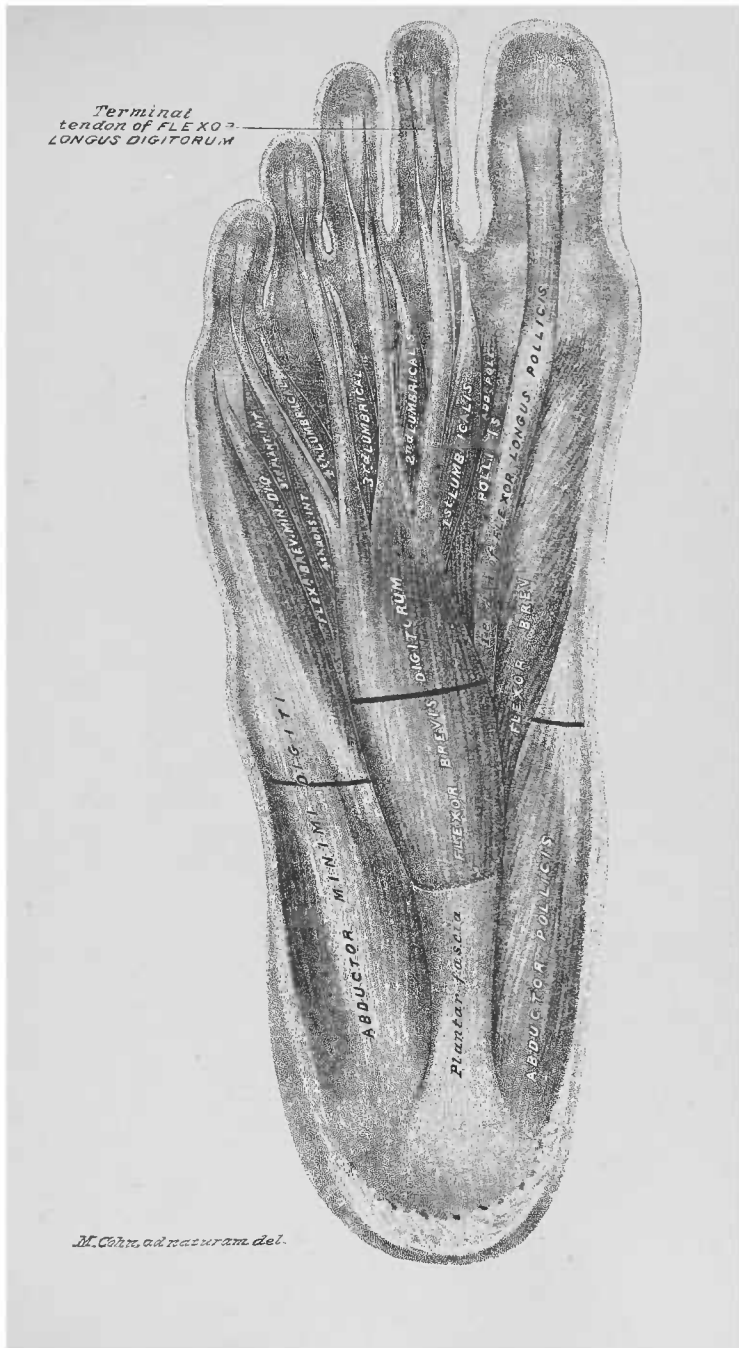
tendons of the extensor longus digitorum muscle of the third, fourth, and fifth digits.

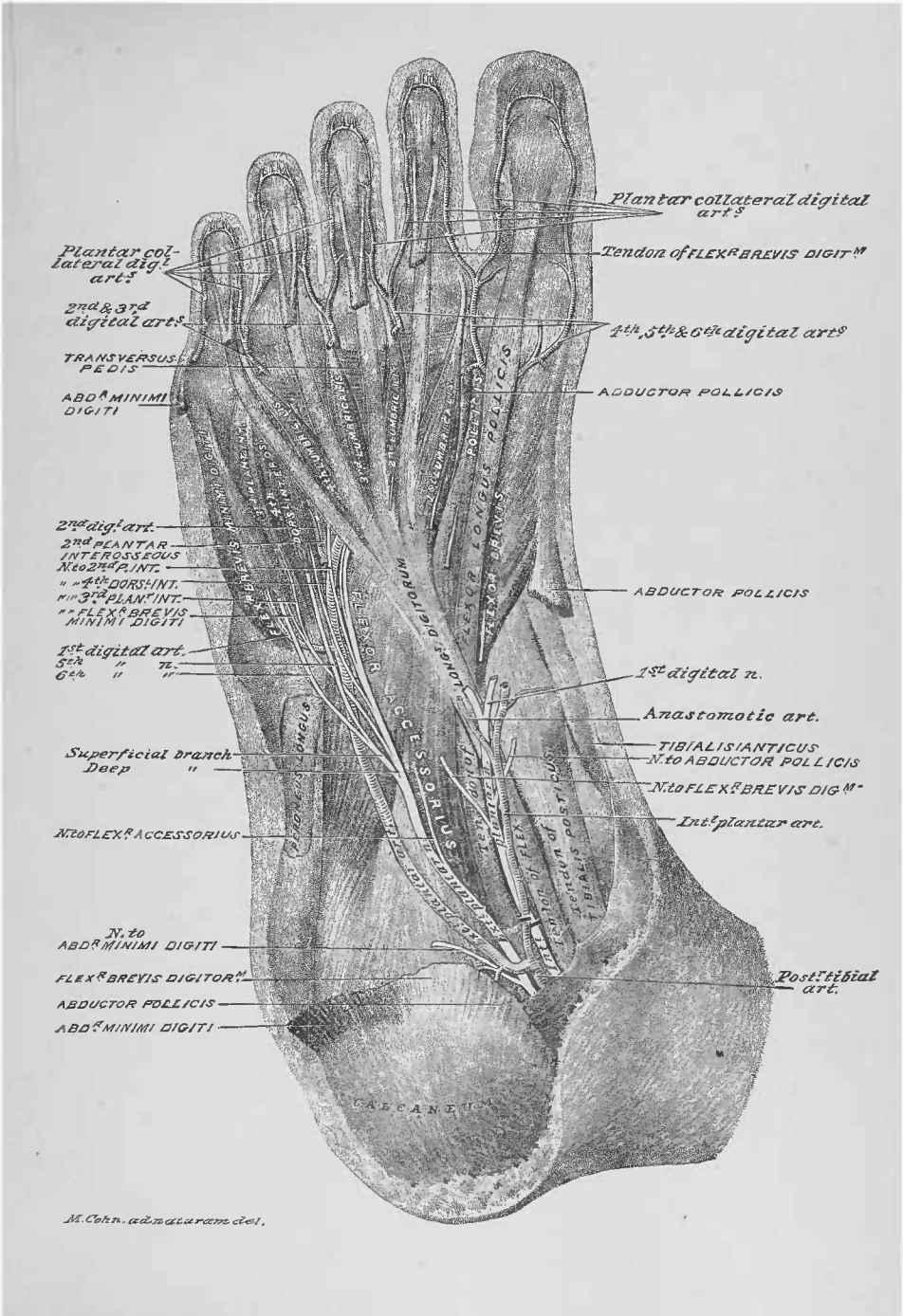73. Compound Digital Extensor Aponeuroses, Fig. 1, Plate 67; Plate 68; Figs. 2 and 3, Plate 82.—Upon the dorsum of each digit, second to fifth inclusive, a compound digital extensor aponeurosis is formed, by the fusion of a terminal tendon of the extensor longus digitorum muscle, a tendon of the extensor brevis digitorum muscle, and fibrous expansions from dorsal and plantar interosseous muscles. The terminal tendon of the extensor longus digitorum of the second digit receives at its inner border the expansion from the first dorsal interosseous; at its outer border the second tendon of the extensor brevis digitorum and the expansion from the tendon of the second dorsal interosseous. The expansion from the first plantar interosseous blends with the inner border of the longus terminal tendon of the third digit; the third tendon of the extensor brevis digitorum and the expansion from the third dorsal interosseous joins its outer border. For the fourth digit, the inner border of the third extensor longus terminal tendon receives the expansion from the second plantar interosseous; to the outer border of the same comes the fourth tendon of the extensor brevis muscle and the expansion from the fourth dorsal interosseous muscle. For the fifth digit, the expansion from the third plantar interosseous muscle fuses with the inner border of the fourth longus terminal tendon. The compound extensor digital aponeurosis of a digit has three attachments: a middle one to the dorsal surface of the base of the phalange; two lateral, which unite for attachment, to the dorsal surface of the base of the phalangette. These aponeuroses lie upon the dorsal ligaments of the digital joints.

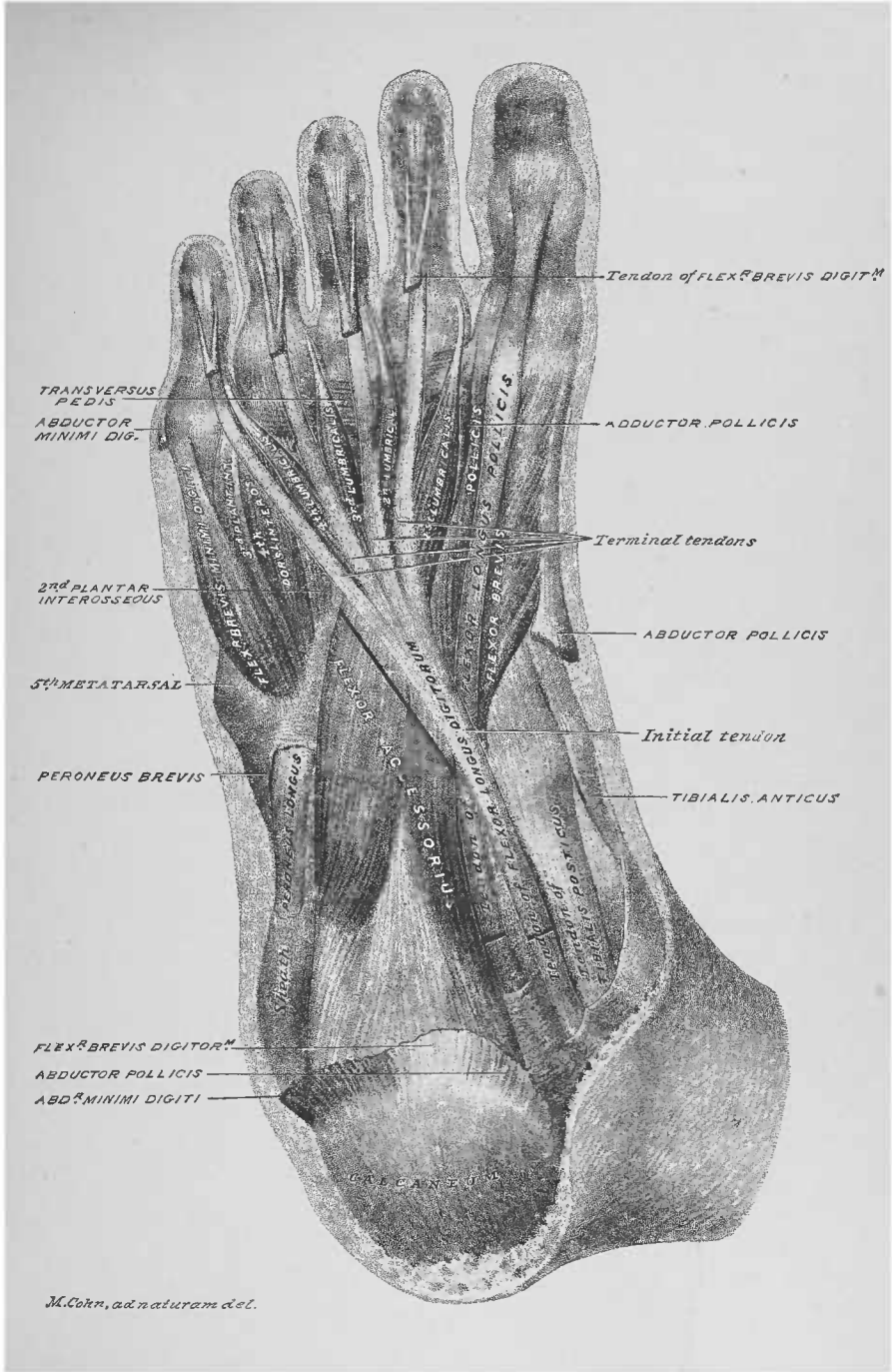
DISSECTION.—After the dissection of the dorsal and plantar regions of the foot be careful to keep the foot wrapped in wet cloths, so that the ligaments of the foot and ankle do not become too dry for subsequent dissection.











TWELFTH DISSECTION.

POSTERIOR REGION OF THE LEG AND THE POP- LITEAL SPACE.

DISSECTION.—Extend the limb with its posterior surface uppermost ; place blocks under the pelvis, thigh, and ankle, respectively ; secure the foot at a right angle to the leg.

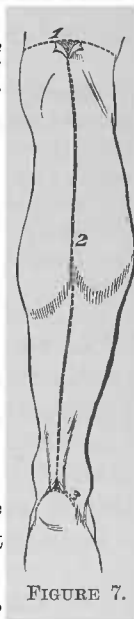Terms of Relation.—*Proximal* (toward the trunk), *distal* (from the trunk), *inner side*, *outer side*, *anterior surface*, and *posterior surface* will be used to indicate the relations of parts.

Bone Areas, Plate 83.—The posterior surface of the calcaneum, the astragalus, the tibia, the fibula, and the distal end of the femur form the osseous plane of this dissection ; with the exception of the astragalus, all these bones afford attachments to muscles presenting in this dissection.

DISSECTION.—Make the skin incisions 1, 2, and 3 of Figure 7, and reflect lateral flaps as indicated. When the dissection of the posterior surface of the leg is consecutive to that of the anterior, the skin flaps will have to be removed. Determine the saphenous veins and nerves.

1. Subcutaneous Tissue, Plate 84.—This plane of tissue presents the ramifications of superficial veins and nerves.

2. External Saphenous Vein.—At about the middle of the leg this vein perforates the fascia ; it runs, through the distal half of the dissection area, to the external malleolus, where it passes, distal to the same, into the minim half of the dorsal surface of the foot (page 124 ; Plate 69).



3. Internal Saphenous Vein.—This vessel appears, for a short distance, along the inner side of the proximal third of the leg.

4. External Saphenous Nerve.—The inner and outer roots of this nerve perforate the fascia, distal to the point of emergence of the external saphenous vein, and unite to form the nerve proper; it accompanies the latter vein.

5. Internal Saphenous Nerve.—This nerve sends branches to the inner half of the posterior area of the leg.

6. Small Sciatic Nerve.—Branches of this nerve perforate the fascia in the popliteal space and the proximal portion of the leg.

DISSECTION.—Section the external saphenous vein and the roots of the external saphenous nerve, where they perforate the fascia (Plate 84). Clear the surface of the fascia free of subcutaneous tissue, veins, and nerves.

7. Superficial Fascia.—This fascia invests the leg, and closes in the popliteal space, by bridging between the muscles which border the same.

DISSECTION.—Incise the superficial fascia, in the same lines as the skin incisions (page 151), and reflect flaps, corresponding to those of the skin, from the subjacent muscles, nerves, etc. Trace the popliteal branches of the small sciatic nerve, that perforate the fascia, to the trunk of the nerve, and follow the ramifications of the terminal branches of the latter; expose the proximal portions of the external saphenous vein, the inner and outer roots of the external saphenous nerve, and the cutaneous branch of the external popliteal nerve.

8. Small Sciatic Nerve, Plate 85.—The distal end of this nerve enters the proximal portion of the leg from the thigh. Its proximal end appears upon the biceps muscle and breaks up into branches, which distribute to the skin of the proximal third of the posterior region of the leg, as shown above; one branch accompanies the external saphenous nerve, with which it anastomoses.

9. External Saphenous Vein, Plates 85 and 86.—This vein may be traced, proximally, between the heads of the gastrocnemius muscle, into the popliteal space.

10. Inner Root of the External Saphenous Nerve.—This nerve has a proximal course along the inner side of the last-described vein; it can be traced to the popliteal space, to where it is given off from the internal popliteal nerve.

11. Outer Root of the External Saphenous Nerve.—This root can be traced upon the outer head of the gastrocnemius muscle, to its proximal origin from the cutaneous branch of the external popliteal nerve.

12. Cutaneous Branch of the External Popliteal Nerve.—This nerve lies upon the outer head of the gastrocnemius muscle, emerging from the outer side of the popliteal space, where it is given off from the inner side of the external popliteal nerve. Its branches perforate the fascia to distribute to the outer side of the leg; some of its branches are projected into the outer antero-lateral area of the leg (page 125; Plate 69).

DISSECTION.—Clear the surface of the gastrocnemius muscle, preserving the ramifications of the four last-described nerves, and the proximal end of the external saphenous vein.

13. Gastrocnemius Muscle, Plates 83, 85, and 86.—This muscle occupies the proximal half of the posterior region of the leg. At its proximal end it presents two diverging portions—the outer and the inner heads—which pass to be attached to the posterior surface of the femur, at the proximal side of the condyles of that bone. Its posterior surface presents a longitudinal-median furrow, which lodges the external saphenous vein, the inner root of the external saphenous nerve, and the terminal branch of the small sciatic nerve. At its distal end the muscle forms a flat tendon, which fuses with the tendon of the soleus muscle to form the tendo Achillis.

DISSECTION.—Section the small sciatic nerve (Plate 85) and remove its distal portion. Clear the muscles forming the proximal boundaries of the popliteal space. Trace the external popliteal nerve, also the internal saphenous nerve and vein.

14. Biceps Muscle, Fig. 2, Plate 67; Plates 85 to 88, inclusive, and Plate 90.—The distal portion of this muscle forms the outer boundary of the proximal half of the popliteal space; it may be traced to its attachment to the proximal end of the fibula.

15. Vastus Externus Muscle, Plates 85 to 88, inclusive, and Plate 90.—A portion of the distal end of this muscle presents to the outer side of the exposed part of the biceps muscle

16. Semimembranosus Muscle, Plates 83, 85 to 88, inclusive, and Plate 90.—Proximal to the inner head of the gastrocnemius muscle the distal portion of this muscle appears, forming the inner boundary of the proximal half of the popliteal space.

17. Semitendinosus Muscle, Fig. 1, Plate 67; Plates 85 to 88, inclusive, and Plate 90.—The distal portion of this muscle lies upon the posterior surface of the last-described muscle, winding, anteriorly, between the inner head of the gastrocnemius and the semimembranosus muscles.

18. Gracilis Muscle.—The distal end of this muscle runs along the inner side of the semimembranosus muscle.

19. Sartorius Muscle.—The distal portion of this muscle presents, anterior to the last-described muscle.

20. Internal Saphenous Nerve, Plate 86.—This nerve, before described (page 125; Plate 70), lies along the inner side of the proximal portion of the dissection area, appearing at the posterior border of the distal end of the sartorius muscle.

21. Internal Saphenous Vein.—This vein, before described (page 125) and illustrated (Plate 70), joins the internal saphenous nerve at the inner side of the leg, lying anterior to it. It enters the leg opposite the anterior border of the distal end of the sartorius muscle.

DISSECTION.—Section (Plate 86) the proximal ends of the cutaneous branch of the external popliteal nerve, the external saphenous vein, the inner root of the external saphenous nerve, and the internal saphenous vein and nerve. Cut away the distal portions of these nerves and veins. Semiflex the knee-joint and draw the muscles bounding the popliteal space to either side; determine the nerves and vessels contained in the popliteal space. In cleaning the exposed portion of the plantaris muscle preserve its nerve.

22. Popliteal Space.—This space approaches the shape of the diamond-figure on a playing card. Its distal boundaries are: to the inner side, the inner head of the gastrocnemius muscle; to the outer side, the plantaris muscle and the outer

head of the gastrocnemius muscle. Its proximal boundaries are : the semimembranosus muscle to the inner side ; the biceps muscle to the outer side. The floor of the space is formed by the posterior surface of the distal end of the shaft of the femur, and the exterior surface of the posterior ligament of the knee-joint.

23. External Popliteal Nerve, Plates 85 to 88, inclusive, and Plate 90.—This nerve emerges from the popliteal space, in the groove between the outer head of the gastrocnemius muscle and the distal end of the biceps muscle, giving off a cutaneous branch (page 153 ; Plates 85 and 86). It winds round the proximal end of the shaft of the fibula, through the substance of the peroneus longus muscle, where it divides into the anterior tibial and the musculo-cutaneous nerves (page 131 ; Plates 72 and 74) ; followed to its proximal end, it is seen to arise from the bifurcation of the great sciatic nerve.

24. Internal Popliteal Nerve, Plates 85 and 86.—This, the largest of the two popliteal nerves, arises from the bifurcation of the great sciatic nerve ; it has a longitudinal course through the posterior plane of the popliteal space. It gives off, from its posterior surface, the inner root of the external saphenous nerve (page 153).

25. Nerve to the Plantaris Muscle.—This nerve is given off from the outer side of the internal popliteal nerve ; it passes directly to the inner face of the muscle.

26. Nerves to the Gastrocnemius Muscle, Plate 87.—A branch from the posterior surface of the internal popliteal nerve is projected between the heads of the gastrocnemius muscle : from its sides the heads of the muscle are supplied ; the branch itself is continued to the anterior surface of the gastrocnemius muscle, to supply the soleus muscle.

DISSECTION.—Hook the internal popliteal nerve aside, and dissect out the popliteal vein and its tributary branches.

27. Popliteal Vein, Plate 86.—This vein takes a longitudinal course, through the popliteal space, in a plane anterior to the internal popliteal nerve ; it enters at the middle of the distal limit of the space, and passes toward the inner side of

its proximal limit. It receives the external saphenous vein (Plates 85 and 86) and the venæ comites of the branches of the popliteal artery. It leaves the popliteal space, at its proximal limit, by the femoral opening in the tendon of the adductor magnus muscle (page 118 ; Plates 64 and 65) ; at the latter opening it lies to the outer side of the popliteal artery.

DISSECTION.—Section the veins tributary to the popliteal vein, and cut them away. Raise and hook aside the vein from the popliteal artery.

28. Popliteal Artery, Plates 86, 87, 88, and 90.—This artery (vena comes) has a longitudinal and oblique course, through the popliteal space, in a plane anterior to the popliteal vein ; it enters the space at the femoral opening in the adductor magnus muscle (page 118 ; Plates 64 and 65) ; it lies upon the posterior surface of the distal end of the shaft of the femur, the exterior surface of the posterior ligament of the knee-joint, and the posterior surface of the popliteus muscle.

29. Muscle Branches of the Popliteal Artery.—Superior and inferior muscle branches are supplied by the popliteal artery : the superior to the muscles bordering the proximal half of the popliteal space ; the inferior to the gastrocnemius, the plantaris, and the soleus muscles.

30. Superior Internal and External Articular Arteries.—These arteries (venæ comites) are lateral branches from the proximal portion of the popliteal ; they wind around the sides of the femur to contribute to the peri-articular plexuses of arteries, at the antero-lateral areas of the knee.

DISSECTION.—Clear the superficies of the portions of the muscles and tendons in the distal part of the dissection area.

31. Soleus Muscle, Plate 85.—This muscle presents at the sides of the gastrocnemius muscle ; at its distal end its tendon forms the greater part of the tendo Achillis.

32. Tendon of the Plantaris Muscle.—This tendon runs along the inner border of the tendo Achillis.

33. Peroneus Longus and Peroneus Brevis Muscles, Plates 85 and 87.—The posterior surface of these muscles present



5787

along the fibular border of the soleus and flexor longus pollicis muscles.

34. Flexor Longus Pollicis Muscle.—This muscle appears between the peroneus brevis muscle and the tendo Achillis.

DISSECTION.—Expose the tendons and the posterior tibial vessels and nerve, which are located upon the posterior surface of the distal end of the tibia.

35. Tendon of the Tibialis Posticus Muscle.—Upon the inner portion of the posterior surface of the internal malleolus is lodged this tendon.

36. Tendon of the Flexor Longus Digitorum Muscle.—This tendon runs to the outer side of the last-described tendon, and is superposed upon it.

37. Posterior Tibial Artery.—A portion of this artery (venæ comites) appears along the outer side of, and parallel with, the last-described tendon.

38. Posterior Tibial Nerve.—A portion of this nerve runs along the outer side of the last-described artery, and to the inner side, though in a deeper plane, of the tendo Achillis.

DISSECTION.—Section the gastrocnemius muscle (Plate 85), and reflect its proximal portion; cut away the middle portion of the muscle, by cutting its respective heads distal to the points of entrance of their nerves (Plate 87); follow the nerves from their origins to the heads of the muscle. Clear the plantaris muscle, preserving its nerve and artery. Determine the nerves and vessels to the soleus muscle, and clear the surface of the muscle.

39. Plantaris Muscle, Plates 83, 85, 86, and 87.—This presents a short muscle portion at its proximal end, which is attached to the posterior surface of the distal end of the femur, at the proximal side of the attachment of the outer head of the gastrocnemius muscle. Its long slender tendon has a distal course: for its first portion upon the posterior surface of the inner half of the soleus muscle; for its second portion to the inner side of, and anterior to, the tendo Achillis—to its attachment to the calcaneum.

40. Soleus Muscle, Plates 83, 85, and 87.—This, the largest muscle of the posterior region of the leg, has, at its proximal

end, two attachments: an outer, to the posterior surface of the proximal end of the shaft of the fibula; an inner, to the oblique line on the posterior surface of the proximal third of the shaft of the tibia. Between these proximal attachments the internal popliteal nerve and the popliteal vein and artery pass into the leg, anteriorly to the soleus muscle. The gastrocnemius and soleus muscles (page 153) form the *tendo Achillis*, which is attached to the posterior surface of the calcaneum

41. Nerves to the Soleus Muscle, Plate 87.—These nerves are supplied from the internal popliteal: the inner, the branch from which the gastrocnemius muscle is supplied (page 155), passes, posteriorly to the plantaris muscle, to enter the proximal end of the tibial portion of the muscle, at the outer side of the tendon of the plantaris muscle; the outer, directly from the internal popliteal nerve, passes, anteriorly to the plantaris muscle, to enter the proximal end of the fibular portion of the muscle.

DISSECTION.—Section, as in Plate 88, the inner nerve to the soleus muscle; cut the plantaris muscle distal to the entrance of its vessel and nerve, as in Plates 88 and 90; reflect the tendon of the muscle to its attachment to the calcaneum, where it may be cut away. Section the *tendo Achillis* (Plate 87) and reflect the soleus muscle to its proximal attachments, where they may be cut away, the tibial near the bone, the fibular distal to the point of entrance of its nerve and vessels, as in Plates 88 and 90. Clear the surface of the popliteus muscle. Trace the distal portions of the internal popliteal nerve, the popliteal vein, and the popliteal artery; note the muscle branches of the nerve.

42. Popliteus Muscle, Plates 83, 87, 88 and 90.—This muscle winds from its proximal attachment, at the side of the outer condyle of the femur, to the posterior face of the knee-joint; it widens as it passes to its distal attachment to the tibia, proximal to the oblique line of that bone.

43. Nerves from the Distal Portion of the Internal Popliteal Nerve, Plate 88.—The distal portion of this nerve gives off the following muscle branches: to the popliteus and flexor longus digitorum muscles, from its inner side; to the tibialis posticus muscle, from its outer side.

44. Nerve to the Popliteus Muscle, Plates 88 and 90.—This nerve is given off from the inner side of the internal popliteal nerve and passes directly to the muscle.

45. Intermuscular Fascia.—A layer of fascia separates the deep muscles, vessels, and nerves of the posterior region of the leg from the soleus muscle. It is attached as follows: to the fibula, between the flexor longus pollicis and the peroneus longus and brevis muscles; to the tibia, along the inner side of the flexor longus digitorum muscle.

DISSECTION.—Remove the intermuscular layer of fascia from the subjacent vessels, nerves, and muscles.

46. Posterior Tibial Nerve, Plate 88.—This nerve is the distal continuation of the internal popliteal nerve; it extends from the distal border of the popliteus muscle to the inner side of the calcaneum, where it bifurcates into the internal and the external plantar nerves. In the proximal quarter of its course it gives off, from its outer side, a branch to the flexor longus pollicis muscle; and in its distal quarter, a plantar cutaneous branch.

DISSECTION.—Extend the foot upon the leg (Plate 89). Clear (Plate 88) the surfaces of the flexor longus pollicis and the flexor longus digitorum muscles; trace them into the plantar region of the foot (Plate 89). Follow the nerves to these muscles from the distal portion of the internal popliteal nerve, and the posterior tibial nerve.

47. Flexor Longus Pollicis Muscle, Plates 83, 75, 88 and 89.—This muscle is attached to the distal two-thirds of the posterior surface of the shaft of the fibula. Its distal, tendinous, portion passes over the ankle (Plate 89), to enter the plantar region of the foot, by a groove in the posterior border of the astragalus (Plate 75.) Its course, relations, and distal attachments, in the plantar region, were before described (pages 138, 142, and 144) and illustrated (Plates 79 and 80).

48. Nerves to the Flexor Longus Pollicis Muscle, Plate 88.—The origin of the trunk of these nerves was described above; the nerves can now be traced to the muscle.

49. Flexor Longus Digitorum Muscle, Plates 83, 75, 88 and 89.—The proximal end of this muscle is attached to the posterior surface of the distal two-thirds of the shaft of the tibia. Its distal end presents its initial tendon upon the posterior surface of the internal malleolus, where it enters the plantar region of the foot, distal to the malleolus (Plate 89); its plan-

tar course, relations, division into four terminal tendons, and the digital attachments of the latter, were before described (pages 139 and 142) and illustrated (Plates 79 and 80).

50. Nerves to the Flexor Longus Digitorum Muscle, Plate 88.—These nerves may now be traced to the muscle: one from the internal popliteal nerve (page 158); the other from the posterior tibial branch to the flexor longus pollicis muscle.

DISSECTION.—Hook the posterior tibial nerve to the inner side; dissect away the (*venæ comites*) of the posterior tibial and peroneal arteries; note the branches of the distal portion of the popliteal artery and its bifurcation at the lower border of the popliteus muscle. Follow the anterior tibial, the posterior tibial, and the peroneal arteries.

51. Popliteal Artery, Plates 88 and 90.—The distal termination of this artery is at the distal border of the popliteus muscle, where it bifurcates into the anterior and the posterior tibial arteries.

52. Inferior Internal and External Articular Arteries.—These arteries (*venæ comites*) are given off from the sides of the distal portion of the popliteal artery. They wind around the sides of the proximal ends of the tibia and fibula, respectively, to contribute to the peri-articular plexuses at the antero-lateral areas of the knee.

53. Anterior Tibial Artery, Plates 88, 90, 73, and 74.—This artery passes to the anterior surface of the tibio-fibular interosseous ligament, through the deficiency at the proximal end of the ligament (pages 129 and 132).

*

54. Posterior Tibial Artery, Plate 88.—This artery (*venæ comites*) has a distal course to the inner side of the calcaneum, where it bifurcates into the internal and the external plantar arteries (pages 139 and 140; Plates 79 and 81). It is lodged between the flexor longus pollicis and the flexor longus digitorum muscles.

55. Peroneal Artery.—This artery (*venæ comites*) is given off from the last-described artery, between the origin of the latter and the proximal end of the flexor longus pollicis muscle; it runs parallel with, and to the outer side of, its parent trunk; it passes to the anterior surface of the pollicis muscle.

* See Appendix, 1.

DISSECTION.—Clear the posterior surface of the peroneus longus and brevis muscles; determine the continuity of the two muscles from the outer side of the leg into the plantar region of the foot (Plate 89).

56. Peroneus Longus Muscle, Fig. 2, Plate 67; Plates 75, 80, 88, 89, and 90.—The anterior surface of this muscle has been described (page 129) and illustrated (Plates 72, 73, and 74). The posterior surface of the muscle occupies the proximal half of the outer side of the leg. It is attached to the proximal half of the outer side of the shaft of the fibula; its tendon commences at about the middle of the leg and is continued to the posterior surface of the external malleolus, distal to which it winds to the minim border of the tarsal region of the foot, where it enters a groove at the outer side of the cuboid bone; by this groove it is directed obliquely across the bases of the metatarsal bones, to its distal attachment to the outer side of the base of the first metatarsal bone (Plates 75, and 79 to 82, inclusive). Where lodged in the groove of the cuboid bone the tendon contains a sesamoid bone. In the plantar region, the tendon of the muscle is held in its osseous groove by a fibrous sheath, which is formed by the distal end of the long calcaneo-cuboid ligament.

57. Peroneus Brevis Muscle.—The anterior surface of this muscle has been described (page 129) and illustrated (Plates 72, 73, and 74). It is attached to the distal half of the outer side of the shaft of the fibula. Its tendon lies upon the posterior surface of the external malleolus, distal to which it winds (Plate 89) to the minim border of the tarsal region, where it passes to its distal attachment, at the base of the fifth metatarsal bone.

DISSECTION.—Cut the sutures uniting the cut tendons of the flexor longus pollicis and the flexor longus digitorum muscles (page 149). Reflect the proximal portions of these muscles and cut them away from their areas of bone attachment (Plate 83). Cut the posterior tibial nerve opposite the tibial attachment of the soleus muscle (Plate 90). Section the posterior tibial artery, distal to its giving off of the peroneal artery (Plate 90). Trace the peroneal artery and its branches.

58. Peroneal Artery, Plates 88 and 90.—This artery (venæ comites) has a distal course parallel with, and to the inner side of, the fibula, between the flexor longus pollicis muscle, pos-

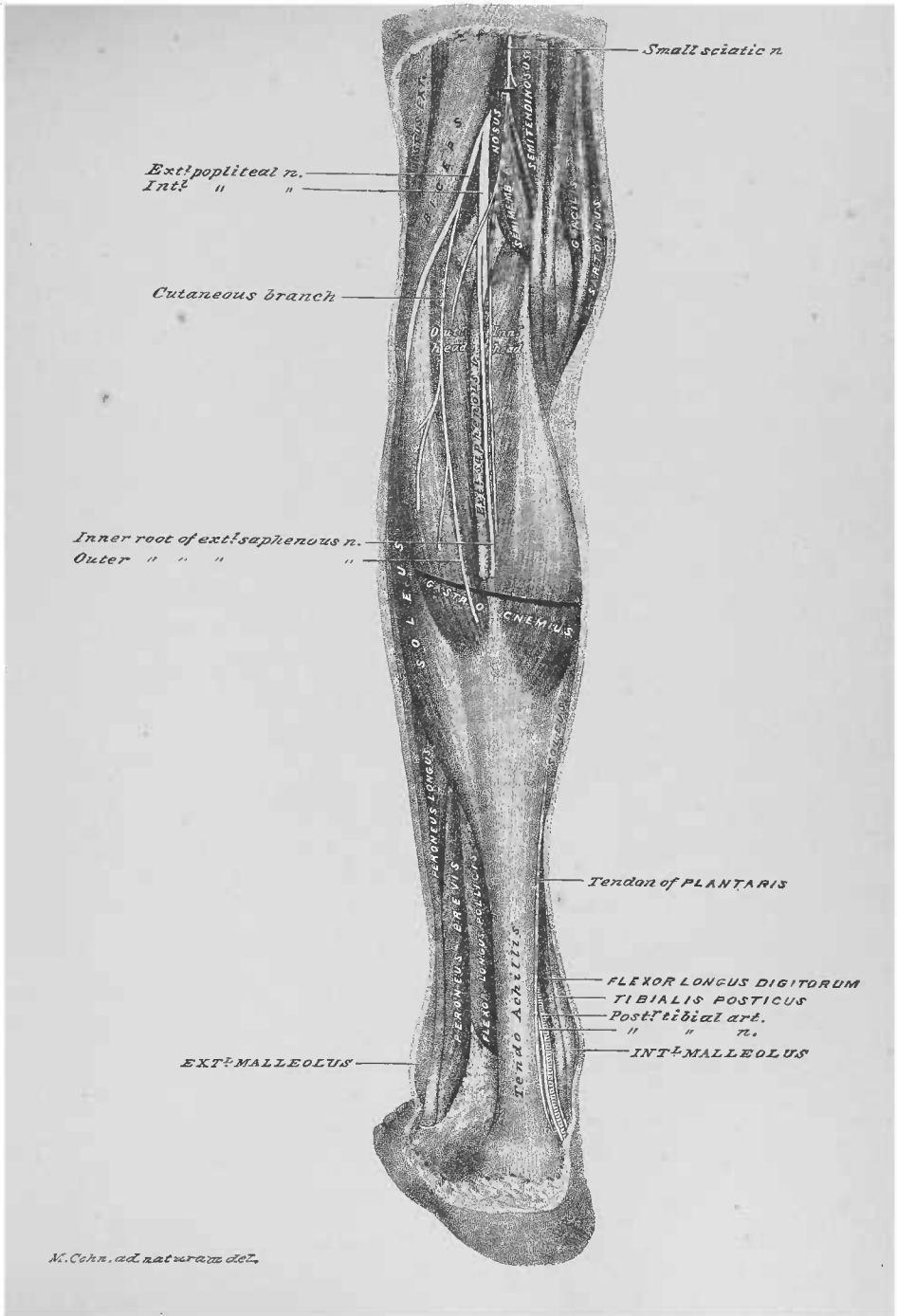
teriorly, and the tibialis posticus muscle, anteriorly. It affords branches to contiguous muscles, and terminates, at the distal limit of the tibio-fibular interosseous space, by bifurcating into the anterior and the posterior peroneal arteries.

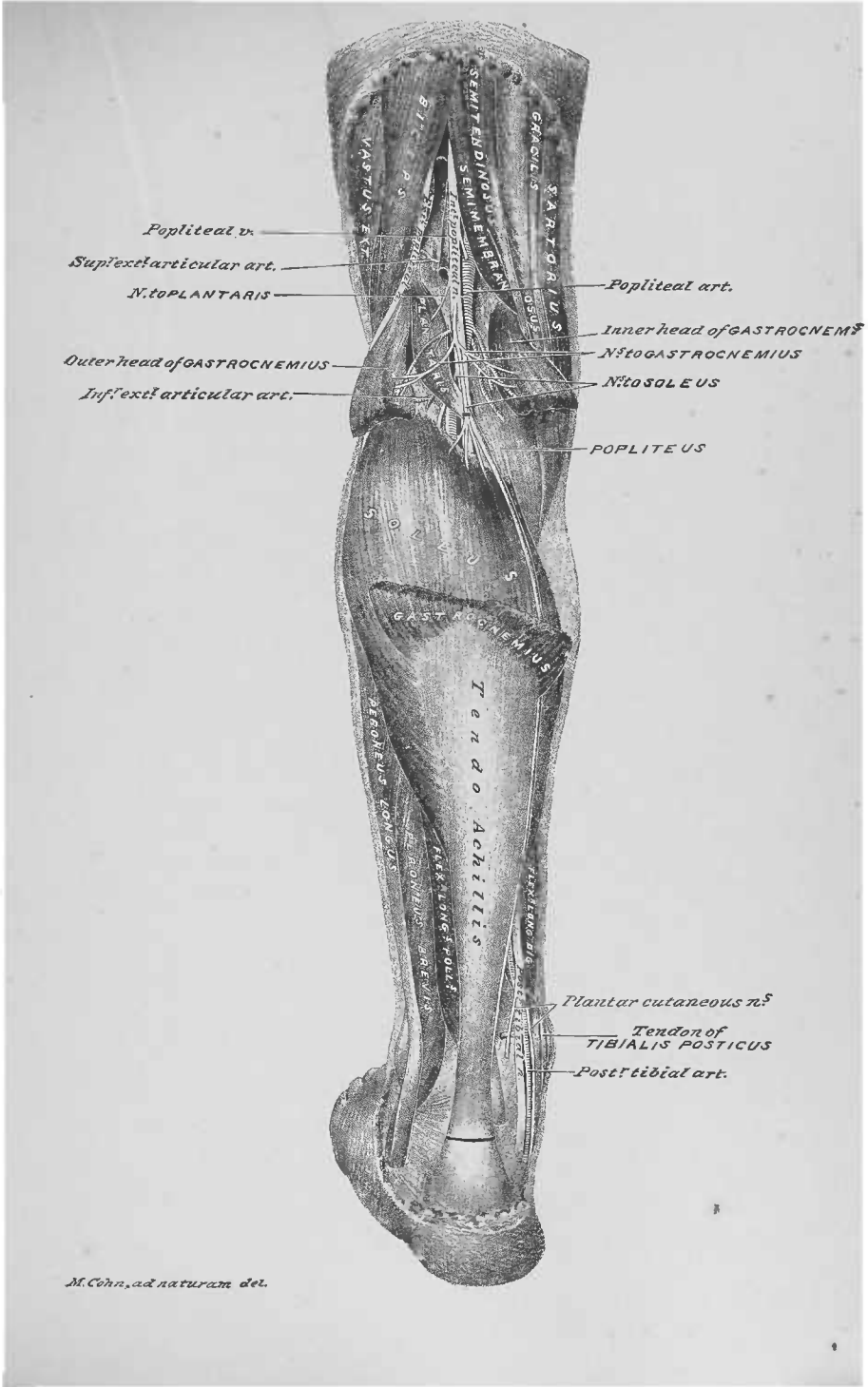
59. Anterior Peroneal Artery, Plate 90.—This artery (*venæ comites*) was seen at the anterior surface of the leg (page 132), and illustrated (Fig. 1, Plate 73 and Plate 74). It passes to the anterior surface of the leg, through a deficiency at the distal end of the tibio-fibular interosseous ligament.

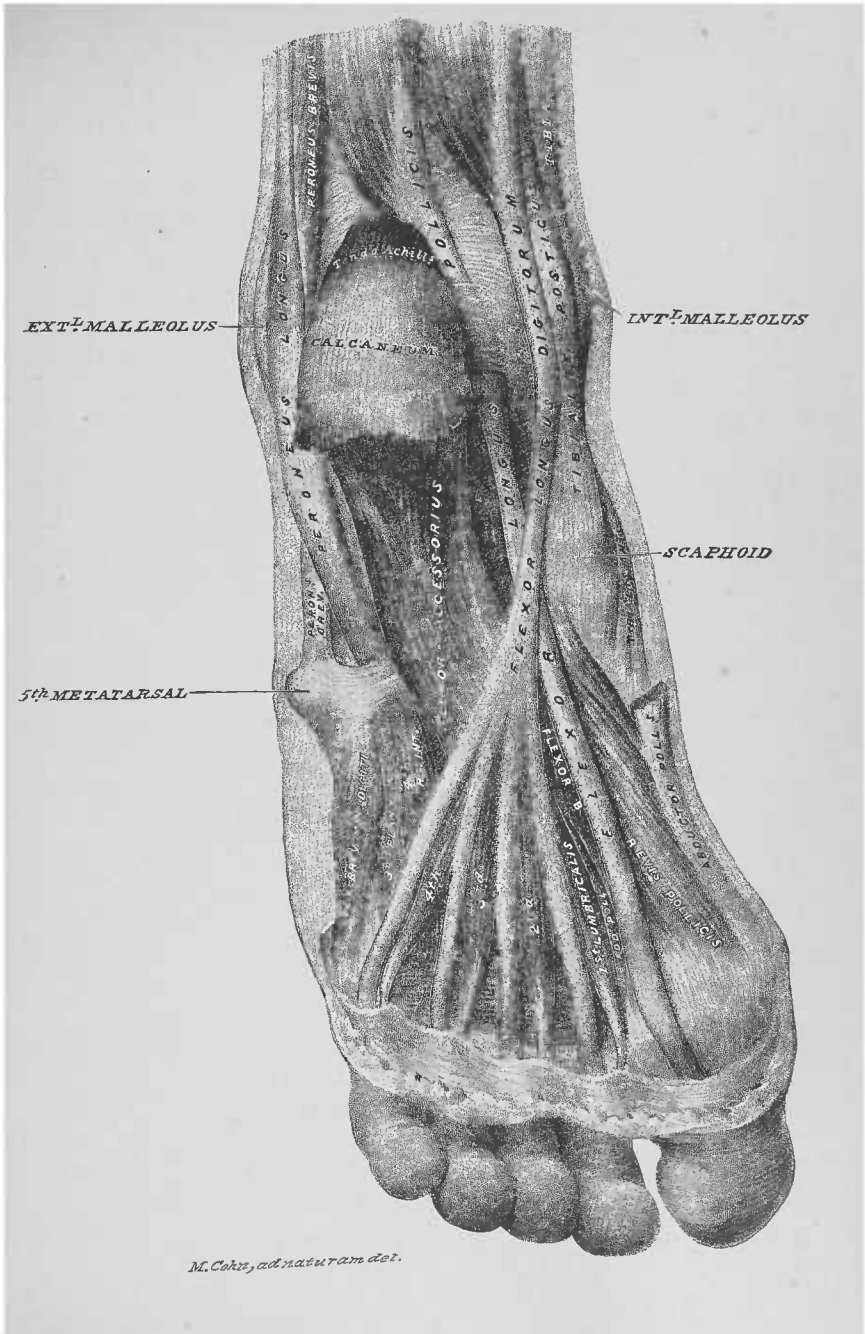
60. Posterior Peroneal Artery.—This artery (*venæ comites*) is a small vessel upon the posterior surface of the ankle-joint, between the tendo Achillis and the tendons of the peronei muscles.

DISSECTION.—Clear the posterior surface of the tibialis posticus muscle and follow its tendon into the plantar region of the foot.

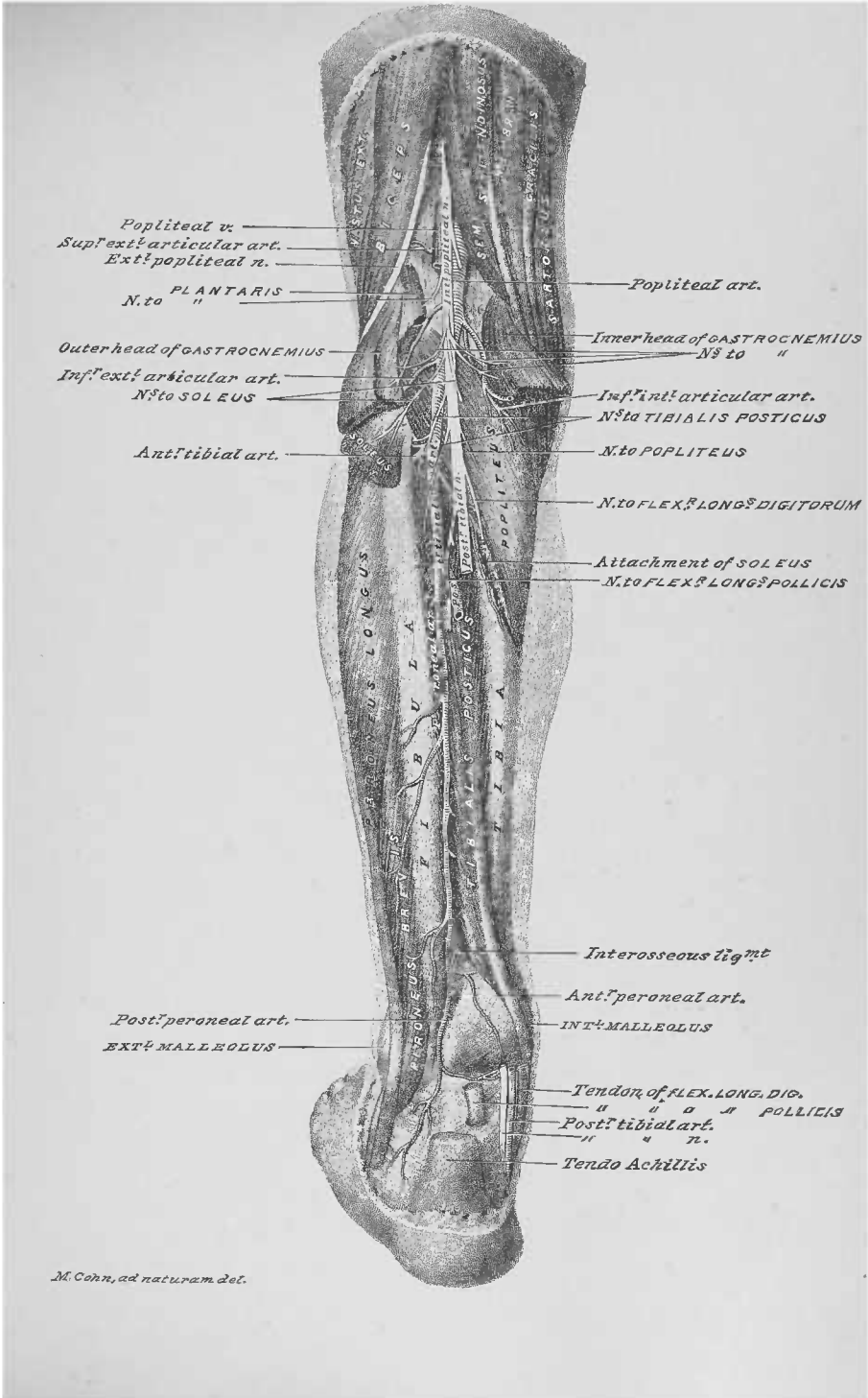
61. Tibialis Posticus Muscle, Plates 75, 79 to 82 inclusive, 83, and 87 to 90, inclusive.—This muscle occupies the posterior surface of the tibio-fibular interosseous ligament (Plate 90); it is attached to the proximal half of the ligament and the adjoining surfaces of the tibia and fibula (Plate 83). Its tendon lies upon the posterior surface of the internal malleolus (Plates 85, 87, 88 and 89), distal to which it winds to reach the pollex border of the tarsal region of the foot (Plate 89). It is attached, primarily, to the tubercle of the scaphoid bone (Plates 75, 79 to 82, inclusive, and 89); secondarily, by outer and distal expansions, which are described at pages 182 and 183, and illustrated Plate 105, and Fig. 1, Plate 106.







M. Coke, ad naturam del.



THIRTEENTH DISSECTION.

GLUTEAL REGION AND POSTERIOR REGION OF THE THIGH.

DISSECTION.—Place a block under the anterior of the pelvis; extend the limb, rotate the thigh inwards, and let the knee, leg, and foot rest upon the table.

Terms of Relation.—To the gluteal region the general terms of relation are applicable (page 2); to the thigh region the terms *proximal*, *distal*, *inner side*, *outer side*, *anterior surface* and *posterior surface* will be applied.

Bone Areas, Plate 91.—The exteriors of the os innominatum, the sacrum, and the coccyx, and the posterior surfaces of the femur and the proximal ends of the tibia and fibula form the osseous plane of the dissection. All these bones afford areas for muscle attachments.

DISSECTION.—Make the skin incisions 1, 2, and 3 of Figure 8, and reflect lateral flaps as indicated. Where the dissection of the anterior of the thigh has been made, the skin may be dissected off.

1. Subcutaneous Tissue.—This tissue is thicker and denser than that of the anterior of the thigh; the veins and nerves are much smaller and less numerous.

DISSECTION.—Clear away the subcutaneous tissue from the fascia, preserving, as far as possible, the subcutaneous nerves and veins.

2. Subcutaneous Nerves, Plate 92.—Branches of the external cutaneous nerve, from the lumbar plexus (page 109;

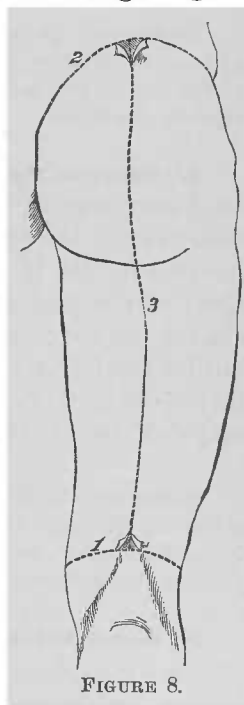


Plate 60), wind over the outer border of the thigh. Branches of the small sciatic nerve perforate the fascia, in the outer and inner halves of the posterior region of the thigh; branches of the latter nerve also wind over the inferior border of the gluteus maximus muscle, to ramify superiorly. Terminal branches of the twelfth dorsal, the ilio-hypogastric and the lumbar spinal nerves enter the gluteal region at its superior limit; posterior branches of the sacral spinal nerves appear near the median line.

3. Fascia Lata.—The posterior portion of the fascia lata forms the fascial plane of the gluteal region and the posterior region of the thigh; its anterior portion, with which the posterior is continuous, was before described (page 109) and illustrated (Plate 60).

DISSECTION.—Abduct the limb, so as to bring the inner side of the leg against the border of the table. Incise and dissect off the fascia lata of the gluteal region, parallel with the fibres of the gluteus maximus muscle, thereby exposing the latter.

4. Gluteus Maximus Muscle, Plates 91, 93, and 94.—This is an oblong muscle, which lies obliquely across the gluteal region, constituting the principal mass of the buttock. Inferior to its inferior border is the gluteal fold, which forms the proximal limit of the posterior region of the thigh. The muscle is included between two layers of the fascia lata: at its superior border the fascia splits to include the muscle, and unites again into a single layer at its inferior limit; upon the trochanter major (Plate 94) the muscle is attached to the fascia.

DISSECTION.—Make an incision through the fascia lata of the posterior surface of the thigh, corresponding to the line of skin incision 3, of Figure 8 (page 163); reflect lateral flaps from the subjacent muscles. Be careful to preserve the small sciatic nerve.

5. Small Sciatic Nerve, Plates 92 and 94.—This nerve emerges into the posterior region of the thigh, at the inferior border, and from the anterior surface, of the gluteus maximus muscle; it takes a distal course between the fascia lata and the surface of the biceps muscle (long head), giving off lateral branches, described above, which perforate the fascia, to reach the subcutaneous tissue. Its branches continue into the sub-

cutaneous plane of the proximal portion of the posterior region of the leg (page 152; Plate 84).

DISSECTION.—Replace the limb upon the table. Section the small sciatic nerve at its proximal end (Plate 94); cut its distal portion away.

6. Vastus Externus Muscle, Plates 91 and 94.—The posterior surface of this muscle occupies the outer border of the posterior of the thigh—from the trochanter major to within a short distance of the outer condyle of the femur; it is attached to the outer lip of the linea aspera of the femur.

7. Biceps Muscle, Plate 94.—The long head of this muscle is projected into the posterior region of the thigh, from the anterior surface and inferior border of the gluteus maximus muscle; it takes an oblique course to the outer side of the knee. A part of the attachment of its short head—to the linea aspera of the femur—is seen between its long head and the vastus externus muscle.

8. Semitendinosus Muscle.—This muscle appears from the anterior surface of the gluteus maximus muscle, at the inferior border of the latter; it runs along the inner side of the long head of the biceps, to which it is apposed, to about the distal third of the thigh, where the two diverge—the semitendinosus passing to the inner side of the knee.

9. Gracilis Muscle.—This muscle presents at the internal surface of the thigh (page 111; Plates 61 to 65, inclusive). Its posterior edge forms the inner border of the posterior surface of the thigh; its distal end may be traced to its attachment to the inner tuberosity of the tibia and the fascia of the leg.

10. Semimembranosus Muscle.—This muscle is lodged in a plane anterior to the biceps (long head) and the semimembranosus muscles. It is projected from the anterior surface of the gluteus maximus muscle: the proximal half of its inner portion occupies the interval between the semitendinosus and the gracilis muscles; its distal portion appears in the divergence of the semitendinosus and biceps muscles. A portion of its anterior surface appeared in the dissection of the an-

terior region of the thigh, between the adductor magnus and the gracilis muscles (page 120; Plates 64 and 65).

11. Adductor Magnus Muscle.—This muscle, though in a plane anterior to the three last-described muscles, presents at two points distal to the inferior border of the gluteus maximus muscle: in the proximal angle formed by the gracilis and the semimembranosus muscles; and in the proximal angle between the long and the short heads of the biceps.

12. Popliteal Space.—The popliteal space, with its contents, *in situ*, is described (page 154) and illustrated (Plates 85 and 86); it is reproduced in this dissection to enable the appreciation of the continuity of parts from the thigh to the leg.

DISSECTION.—Section the gluteus maximus muscle (Plate 93) and reflect its portions, externally and internally. In raising the portions of the muscle, note the bursæ beneath the muscle; also the vessels and nerves that enter its deep surface. Cut away the inferior part of its external portion, close to its femoral attachment, and the superior part thereof with the fascia lata, to which it is attached; cut the vessels and nerves entering its anterior surface.

13. Gluteus Maximus Muscle, Plates 91, 93, 94, and 95.—The reflection of the external portion of this muscle will determine its attachment to the fascia lata of the thigh, superiorly, and to the femur, inferiorly—at the inner side of the proximal portion of the outer lip of the linea aspera. Its internal attachments are: to the exterior surfaces of the postero-internal border of the os innominatum, and the external borders of the sacrum and coccyx; to the posterior surfaces of the sacro-iliac and great sacro-sciatic ligaments.

DISSECTION.—Abduct the limb, so as to bring the inner side of the leg against the border of the table. Clear the area anterior to the gluteus maximus muscle, so as to expose the bursæ under the muscle, the great sacro-sciatic ligament, the pyriformis muscle, the proximal portion of the small sciatic nerve, the inferior gluteal nerve, the great sciatic nerve, the sciatic artery and its branches, the superficial branch of the gluteal artery, and the posterior surface of the gluteus medius muscle. Cut away the internal portion of the gluteus maximus muscle, as in Plate 95.

14. Bursæ Beneath the Gluteus Maximus Muscle, Plate 96; and Fig. 1, Plate 4.—Two large bursæ present beneath the gluteus maximus muscle: one on the tuberosity of the ischium; the other upon the trochanter major of the femur.

15. Great Sacro-Sciatic Ligament, Plates 95, 99, and 100.—This ligament extends from the exterior of the tuberosity of the ischium to the posterior surfaces of the sacrum, near its external border, and of the posterior inferior spinous process of the ilium portion of the os innominatum.

16. Piriformis Muscle, Plates 91 and 95 to 100, inclusive.—The internal attachment of this muscle, at the interior of the pelvis, was before described (page 82) and illustrated (Plate 42; Fig. 1, Plate 45; and Fig. 1, Plate 46). The muscle is projected from the pelvis into the gluteal region, through the great sacro-sciatic foramen; it has an attachment to the superior border of the foramen. It takes a somewhat oblique course, externally, to its attachment to the antero-superior part of the internal surface of the trochanter major of the femur.

17. Small Sciatic Nerve, Plates 95 to 100, inclusive.—The proximal portion of this nerve, anterior to the gluteus maximus muscle, may be traced to its point of emergence into the gluteal region, from the anterior of, and at the inferior border of, the internal half of the piriformis muscle. It gives off the inferior pudendal nerve, which winds inferiorly to the tuberosity of the ischium to reach the external genitalia (pages 16 and 32; Plates 6 and 13).

18. Inferior Gluteal Nerve.—This nerve emerges into the gluteal region with the last-described nerve. It breaks up into a number of branches, which enter the anterior surface of the superior part of the gluteus maximus muscle; so close is the relation of the proximal end of this nerve and the small sciatic nerve, that it requires care to separate them.

19. Sciatic Artery.—In the reflection of the portions of the gluteus maximus muscle arterial branches were cut, which entered the inferior part of its anterior surface; the stumps may be followed to the sciatic artery (*venæ comites*), which enters the gluteal region at the inferior border of the piriformis muscle; at the latter point it is internal to, and in close relation with, the small sciatic nerve. Besides affording branches to the gluteus maximus muscle, the trunk of this artery gives off an articular branch (to the hip-joint), which runs, externally, along the inferior border of the piriformis muscle.

The trunk of the artery continues, inferiorly, into the proximal part of the posterior region of the thigh; its course is, externally to the tuberosity of the ischium, parallel with, and superficial to, the great sciatic nerve; to the latter nerve it gives a branch, the *comes nervi ischiadici* (Plates 96 and 97), which enters the nerve. Muscle branches are afforded to contiguous muscles; and terminal branches anastomose with the internal circumflex and the first perforating branch of the profunda femoris artery.

20. Superficial Branch of the Gluteal Artery, Plates 95 and 99.—Stumps of arteries present, which were cut as they entered the anterior surface of the superior part of the gluteus maximus muscle; they may now be traced to this branch of the gluteal artery (*venæ comites*), at the superior border of the internal portion of the piriformis muscle, between the latter and the gluteus medius muscle.

21. Gluteus Medius Muscle, Plates 91 and 95 to 100, inclusive.—This muscle occupies the interval between the trochanter major of the femur and the anterior two-thirds of the crest of the ilium. The internal third of its posterior surface is overlapped by the gluteus maximus muscle (Plate 93); its external border is covered by the tensor vaginæ femoris muscle (Plate 61). Upon the removal of the latter muscle, its external border presents at the outer side of the proximal portion of the anterior surface of the thigh (Plates 62 to 65, inclusive; and Fig. 2, Plate 66). It is attached, superiorly, to the exterior of the ilium of the os innominatum, between its superior and middle curved lines, being continued to the anterior border of the bone; inferiorly, it narrows to be attached to the superior and external surfaces of the trochanter major of the femur.

DISSECTION.—Section the inferior gluteal nerve, the small sciatic nerve, and the sciatic artery at their superior ends (Plate 97), and dissect away their inferior portions; cut the articular branch of the artery at its origin and leave it *in situ*. Separate the long head of the biceps muscle from the semitendinosus muscle, being careful not to cut away the nerves and arteries that supply them.

22. Long Head of the Biceps Muscle, Fig. 1, Plate 91; Plates 93 to 98, inclusive.—The biceps is the outer, superficial and longitudinal muscle of the posterior surface of the thigh; its proximal portion having two heads: the *long head* is at-

tached to the tuberosity of the ischium, in common with the semitendinosus muscle, taking an oblique course therefrom toward the outer side of the knee; the *short head* lies anteriorly to the long head.

23. Semitendinosus Muscle.—The proximal end of this muscle is fused, for about three or four inches, with the last-described muscle; the two muscles having a common attachment to the postero-inferior border of the tuberosity of the ischium. The muscle takes its course parallel with, and to the inner side of, the long head of the biceps. At about the distal third of the thigh its tendon commences, which diverges from the biceps muscle and passes to the inner side of the knee; it may be traced to its attachment to the inner tuberosity of the tibia (Fig. 1, Plate 67).

DISSECTION.—Flex the leg slightly, and steady it in that position; hook the long head of the biceps muscle to the outer side, and the semitendinosus and semimembranosus muscles to the inner side. Trace the great sciatic nerve through the gluteal region and the posterior region of the thigh; dissect out the muscle branches of the nerve and its terminal bifurcation.

24. Great Sciatic Nerve, Plates 95 to 97, inclusive.—This nerve, the largest in the body, is derived from the sacral plexus; it is projected into the gluteal region, through the great sacro-sciatic foramen, appearing from the anterior of the inferior border of the pyriformis muscle, a little external to the emergence of the inferior gluteal and the small sciatic nerves. In the gluteal region it is lodged upon the posterior surface of the gemellus superior, the obturator internus, the gemellus inferior, and the quadratus femoris muscles; on the latter muscle it lies between the ischium of the os innominatum and the trochanter major of the femur—nearest the former. In the posterior region of the thigh it has a distal course, anterior to the superficial muscles (biceps, semitendinosus, and semimembranosus) and the muscle floor of the posterior region of the thigh—the adductor magnus. At a point to the proximal side of the popliteal space, the nerve bifurcates into the external and the internal popliteal nerves, which have been described (page 155) and illustrated (Plates 85 and 86).

25. Nerves to the Biceps Muscle, Plates 96 and 97.—Two branches are given off from the great sciatic nerve to the heads

of this muscle: to the long head a branch from the inner side of the nerve; to the short head a branch from its outer side, which bifurcates before entering the muscle.

26. Nerve to the Adductor Magnus, the Semimembranosus, and the Semitendinosus Muscles.—Distal to the biceps branches, a nerve is given off from the inner side of the great sciatic, which bifurcates: the short branch supplying the adductor magnus muscle; the long one taking a longitudinal course, and dividing, to supply the semimembranosus and the semitendinosus muscles.

27. Nerve to the Semitendinosus Muscle.—This, the most distal and shortest branch from the great sciatic nerve, passes directly from the inner side of the nerve to the muscle.

DISSECTION.—Cut the proximal ends of the long head of the biceps and the semitendinosus muscle (Plate 96); reflect the muscles, in a distal direction, and cut the nerves and vessels supplying them. Section the long head of the biceps near its junction with the short head; and the semitendinosus near its distal attachment (Plate 96). Clear the surfaces of the short head of the biceps muscle and the semimembranosus muscle.

28. Short Head of the Biceps Muscle, Plates 94, 96, 97, and 98; Fig. 1, Plate 91; Fig. 2, Plate 67.—This head of the biceps muscle is located in a plane anterior to the long head (Plate 94); and in part to the outer side of the latter. It has a longitudinal course, being attached to the linea aspera, along the inner side of the distal two-thirds of its outer lip (Fig. 1, Plate 91). In the distal quarter of the thigh, the two heads of the biceps unite; they then pass as a single muscle over the outer side of the knee, to be attached to the proximal end of the fibula.

29. Semimembranosus Muscle, Plates 94, 96, and 97; Fig. 1, Plate 91.—This muscle, the largest in the posterior region of the thigh, lies to the inner side of the thigh, anterior to the long head of the biceps and the semitendinosus muscles. Its proximal attachment is to the inferior and external surfaces of the tuberosity of the ischium; the muscle takes a longitudinal course to the inner side of the posterior surface of the knee, where it may be traced to a short thick tendon, which is in part attached to the proximal end of the tibia, at the posterior plane

of its inner tuberosity ; it also contributes to the posterior ligament of the knee-joint.

DISSECTION.—Cut the proximal ends of the great sciatic nerve and the semimembranosus muscle (Plate 97) ; make a distal reflection of the nerve and muscle ; cut the nerve to the adductor magnus muscle ; cut the semimembranosus muscle near its distal attachment (Plate 97). Cut the perforating arteries and the popliteal artery and its branches, as in Plate 98. Dissect away all arteries of the posterior region of the thigh and popliteal space. Clear the surface of the adductor magnus muscle. Determine the femoral opening, and the openings for the perforating branches and terminal portion of the profunda femoris artery, through the adductor magnus muscle. Find the anastomotica magna artery and the long saphenous nerve at the inner side of the distal portion of the thigh.

30. Adductor Magnus Muscle, Plate 59 ; Fig. 1, Plate 91 ; Plates 93 to 100, inclusive.—The anterior surface of this muscle, described (pages 111 and 119) and illustrated (Plates 61 to 65 inclusive ; and Fig. 2, Plate 66), forms the floor of the anterior region of the thigh ; its posterior surface constitutes the floor of the posterior region of the thigh. Its proximal attachment is to the exterior of the body and of the anterior ramus of the ischium ; its distal attachment is to the inner side of the external lip of the linea aspera of the femur for its whole length from the trochanter major ; it is also attached to the inner condyle of the femur. It is perforated by the femoral artery and vein, and by the perforating branches of the profunda femoris artery.

31. Femoral Opening in the Adductor Magnus Muscle, Plates 96, 97, and 98.—The anterior of this was described (page 118) and illustrated (Plates 64 and 65) ; its posterior view presents in the distal third of the muscle. It transmits, in a distal direction, the femoral artery to become the popliteal ; and in a proximal direction, the popliteal vein to become the femoral. The vein is to the outer side of the artery.

32. Openings in the Adductor Magnus Muscle for the Branches and Terminal Portion of the Profunda Femoris Artery, Plates 63, 64, and 98.—Close along the femoral attachment of the adductor magnus muscle four openings present, at about equal distances, for the transit of the three perforating branches and the terminal portion of the profunda femoris artery ; muscle branches also perforate the muscle.

33. Anastomotica Magna Artery, Plate 98.—This artery (venæ comites) has been described (page 118) and illustrated (Plates 64 and 65) in the anterior region of the thigh. If the dissection of the anterior region of the thigh has not preceded that of the posterior region, this artery will present at the inner side of the tendinous portion of the adductor magnus muscle, to the proximal side of the inner condyle of the femur.

34. Internal Saphenous Nerve.—This nerve was before described (pages 113 and 114), as seen in the anterior region of the thigh. It is now seen, from its posterior aspect, in that portion of its course where it accompanies the last-described artery.

DISSECTION.—Determine the articular branches of the popliteal artery and follow them to the antero-lateral areas of the knee.

35. Articular Branches of the Popliteal Artery.—The articular branches of this artery are five in number: the superior and inferior external articular, the superior and inferior internal articular, and the azygos articular. The four first wind, respectively, to the antero-lateral areas of the knee-joint, to form with the anastomotica magna, from the femoral, and the anterior tibial recurrent (page 132; Plate 74), from the anterior tibial, the deep and superficial peri-articular plexuses of the antero-lateral areas of the knee. The azygos articular branch perforates the posterior ligament of the knee-joint.

DISSECTION.—Clear the surface of the quadratus femoris muscle and find the emergence of the internal circumflex artery at the internal portion of its inferior border.

36. Quadratus Femoris Muscle, Plate 59; Fig. 1, Plate 91; Plates 95 to 100, inclusive.—A small area of the anterior surface of this muscle appeared in the anterior region of the thigh (page 120; Plate 65, and Fig. 2, Plate 66). Its posterior surface presents as an oblong muscle, running transversely, from the anterior surface of the posterior ramus of the ischium (Plate 59), internally, to the posterior surface of the trochanter major of the femur, externally. It has the gemellus inferior muscle superiorly, and the adductor magnus muscle inferiorly.

DISSECTION.—Section the glutæus medius muscle (Plate 95) and reflect its portions, superiorly and inferiorly, to their attachments, where they may be cut away, as in Plate 99; note the vessels entering the anterior surface of the mus-

cle. Follow the ramifications of the deep branches of the gluteal artery and the superior gluteal nerve, from their emergence into the gluteal region to their distribution. Clear the surface of the gluteus minimus muscle.

37. Internal Circumflex Artery, Plate 98.—The terminal portion of this artery (*venæ comites*) enters the inner side of the proximal portion of the posterior region of the thigh, between the quadratus femoris and adductor magnus muscles.

38. Deep Branches of the Gluteal Artery, Plate 99.—This artery (*venæ comites*) appears in the gluteal region superior to the internal portion of the pyriformis muscle, between it and the gluteus minimus muscle; it presents a superior and an inferior portion, which ramify between and supply the gluteus medius, and gluteus minimus muscles; the inferior portion also supplies the tensor *vaginæ femoris* muscle.

39. Superior Gluteal Nerve.—This nerve appears at the superior border of the pyriformis muscle; between it and the gluteus minimus muscle. Its emergence is external to that of the last-described artery. It divides into a superior and an inferior portion; they ramify between the gluteus medius and minimus muscles, and supply the same. The inferior portion also supplies the tensor *vaginæ femoris* muscle.

40. Gluteus Minimus Muscle, Plates 59, 91, 99, and 100.—This muscle is located upon the exterior surface of the ilial portion of the os innominatum, to which it is attached between the middle and the inferior curved lines of that bone (Fig. 1, Plate 91); inferiorly, it is attached to the anterior border of the trochanter major of the femur (Plate 59). Its internal border overlaps the superior border of the pyriformis muscle; its antero-external border is covered by the tensor *vaginæ femoris* muscle (Plate 61); on the removal of the latter it appears at the outer side of the proximal portion of the anterior surface of the thigh (Plates 62 to 65, inclusive; and Fig. 2, Plate 66).

DISSECTION.—Expose the internal pudic vessels and nerve, also the nerve to the obturator internus and the gemellus superior muscles, in the interval between the internal ends of the pyriformis muscle and the great sacro-sciatic ligament. Clear the surfaces of the gemellus superior, the obturator internus, and the gemellus inferior muscles; expose the proximal portion of the great sciatic nerve.

41. Pudic Artery, Plates 95 to 100, inclusive.—In the dissection of the interior of the pelvis this artery is described (page 75) and illustrated (Plates 39 and 40; Fig. 1, Plate 46). Emerging from the anterior surface of the internal portion of the pyriformis muscle it runs over the exterior of the spine of the ischium, and then enters the pelvic cavity by the small sacro-sciatic foramen; after it enters the pelvis, it ramifies upon the obturator internus muscle, along the interior of the external wall of the ischio-rectal fossa; this portion of its course has been described (pages 18 and 33) and illustrated (Plates 7, 13, and 14).

42. Pudic Nerve.—This nerve, branch from the sacral plexus, appears with the last-described artery and accompanies it upon the exterior face of the spine of the ischium; it enters the pelvic cavity, with the artery, by the small sacro-sciatic foramen. Its subsequent course with the artery, along the interior of the external wall of the ischio-rectal fossa, is described (page 18) and illustrated (Plates 7, 13, and 14).

43. Nerve to the Obturator Internus and the Gemellus Superior Muscles.—This nerve arises from the sacral plexus, and accompanies the pudic artery and nerve across the exterior surface of the spine of the ischium; running external to them. It re-enters the pelvis by the small sacro-sciatic foramen to supply the obturator internus muscle; before entering the foramen it sends a branch to the gemellus superior muscle.

44. Obturator Internus Muscle, Fig. 2, Plate 91, and Plates 95 to 100, inclusive.—The internal attachment of the obturator internus muscle and its portion within the pelvic cavity has been described (pages 17 and 84) and illustrated (Plates 39 and 40; and Fig. 1, Plate 46). It is projected into the deep plane of the gluteal region through the small sacro-sciatic foramen; it continues, externally, to its attachment to the trochanter major of the femur (Fig. 2, Plate 91).

45. Gemellus Superior Muscle.—This muscle is attached, internally, to the exterior surface of the spine of the ischium; it continues therefrom, externally, between the obturator internus and the pyriformis muscles, to where it fuses with the tendon of the obturator internus muscle.

46. Gemellus Inferior Muscle.—This muscle is attached, internally, to the exterior surface of the body of the ischium; it continues, externally, between the obturator internus and the quadratus femoris muscles, to where it blends with the tendon of the obturator internus muscle.

47. Compound Tendon of the Obturator Internus, Gemellus Superior, and Gemellus Inferior Muscles.—These three muscles join, at their external ends, forming a compound tendon, which is attached to the anterior portion of the internal face of the trochanter major of the femur (Fig. 2, Plate 91).

DISSECTION.—Section the quadratus femoris muscle (Plate 98), and reflect the portions of the muscle to the tuberosity of the ischium and the trochanter major of the femur, respectively; cut them away, as in Plate 99. Find the nerve and artery entering the anterior surface of the inner portion of the muscle; cut the nerve close to the muscle. Clear the posterior surface of the obturator externus muscle, and determine the internal circumflex artery and its branches.

48. Internal Circumflex Artery, Plates 98, 99, and 100.—This artery (*venæ comites*), branch of the profunda femoris (pages 117 and 119; Plates 63, 64, and 65; and Fig. 2, Plate 66), presents anterior to the quadratus femoris muscle, and there bifurcates; one branch is projected to the posterior region of the thigh between the quadratus femoris and the adductor magnus muscles (page 173); the other is an articular branch, which takes an external, and superior, course to the hip-joint.

49. Obturator Externus Muscle, Plates 95 to 100, inclusive; Plates 59, 66, and 91.—The anterior face of this muscle has been described (page 121) and illustrated (Plates 64, 65, and 66); the posterior face of its external portion is shown, as it appears upon the removal of the quadratus femoris muscle (Plate 99). Internally, it comes from the anterior surface of the pelvis (Plate 59); externally, it passes, parallel with, and inferiorly to the compound tendon of the obturator internus and the gemelli muscles, to its attachment, at the digital fossa on the internal face of the trochanter major of the femur.

DISSECTION.—Section the compound tendon of the obturator internus, the gemellus inferior, and the gemellus superior muscles (Plate 99); reflect the muscles internally. In reflecting the gemellus inferior muscle note its nerve supply. Determine the bursa anterior to the inner portion of the obturator

internus muscle. Cut the obturator internus muscle at the small sacro-sciatic foramen and the gemelli muscles from their internal attachments, as in Plate 100. Section the obturator externus muscle (Plate 99); reflect it internally and cut it where it passes anterior to the tuberosity of the ischium, as in Plate 100.

50. Nerve to the Gemellus Inferior Muscle, Plates 99 and 100.—The nerve to this muscle enters its anterior face; it is a branch of the nerve to the quadratus femoris muscle.

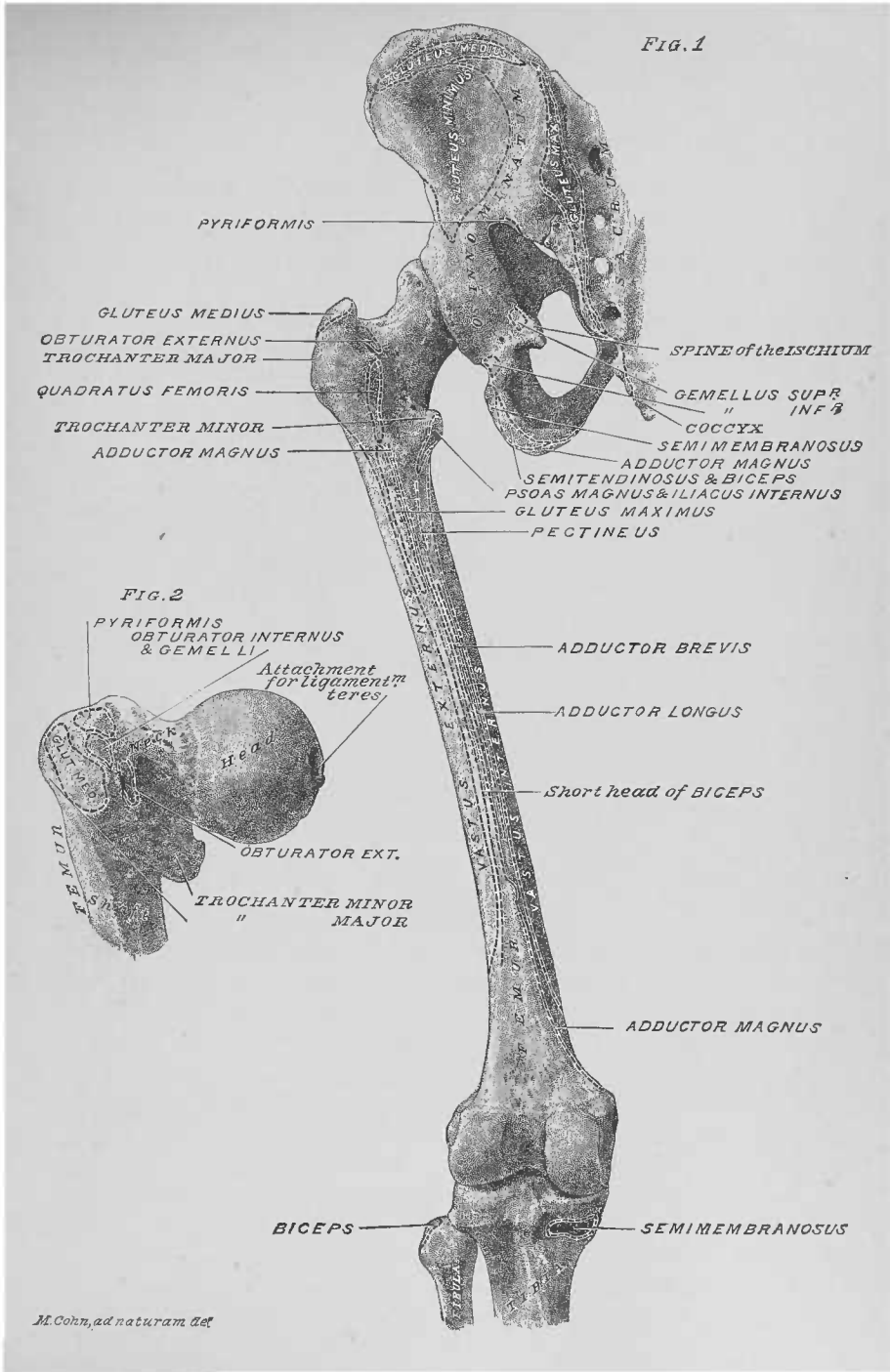
51. Bursa of the Obturator Internus Muscle, Fig. 1, Plate 4.—This large bursa is anterior to the obturator internus muscle, near the small sacro-sciatic foramen.

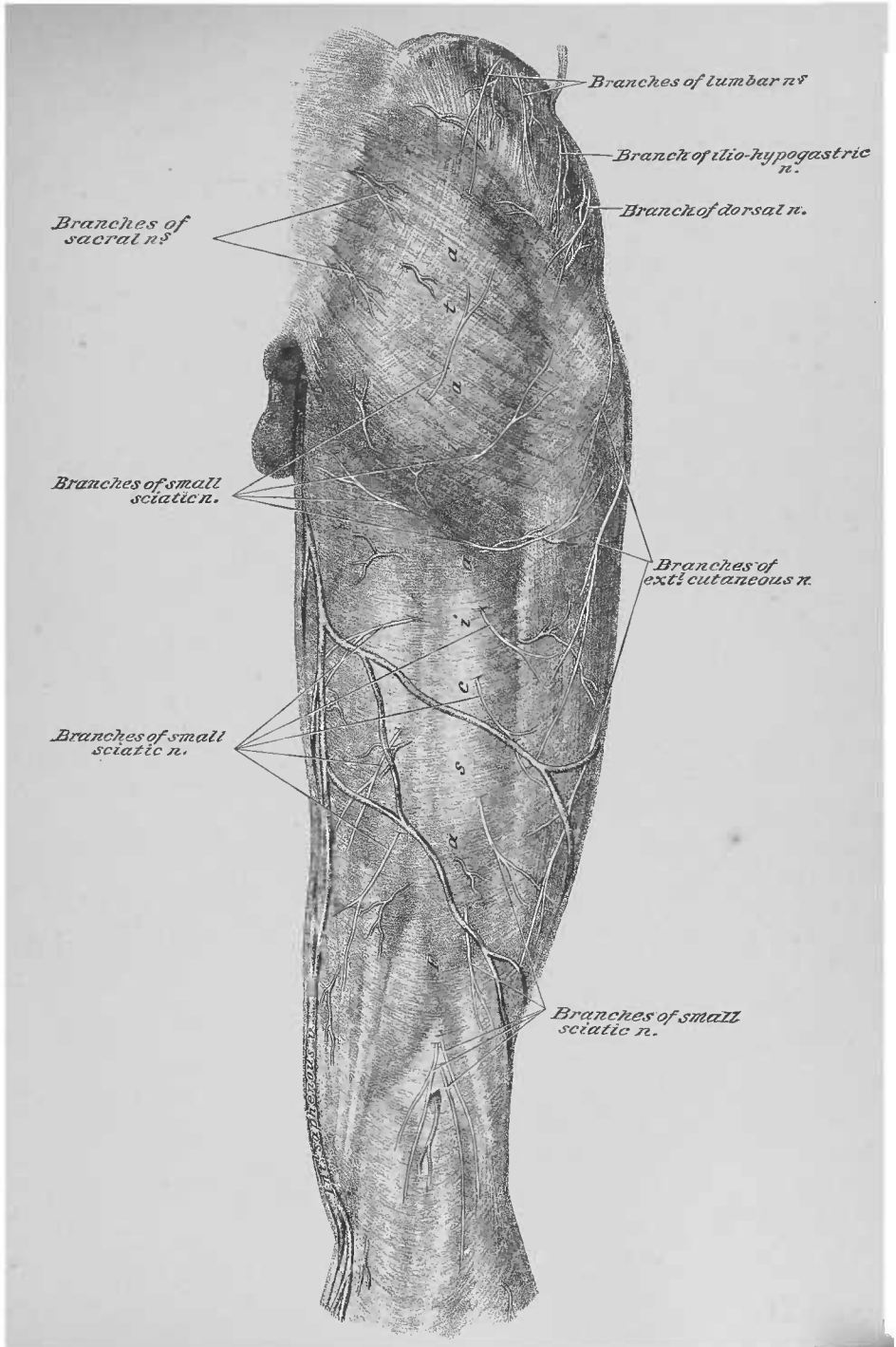
DISSECTION.—Section the gluteal artery and the superior gluteal nerve (Plate 99) and clear away their branches; cut the gluteus minimus muscle (Plate 99) and reflect it, superiorly, to its ilial attachment, from which it may be cut away, as in Plate 100. Section the piriformis muscle (Plate 99) and reflect it internally; cut it close to the great sacro-sciatic foramen, as in Plate 100. Follow the nerve to the quadratus femoris muscle, superiorly (Plate 99). Determine the parts passing through the great and small sacro-sciatic foramina.

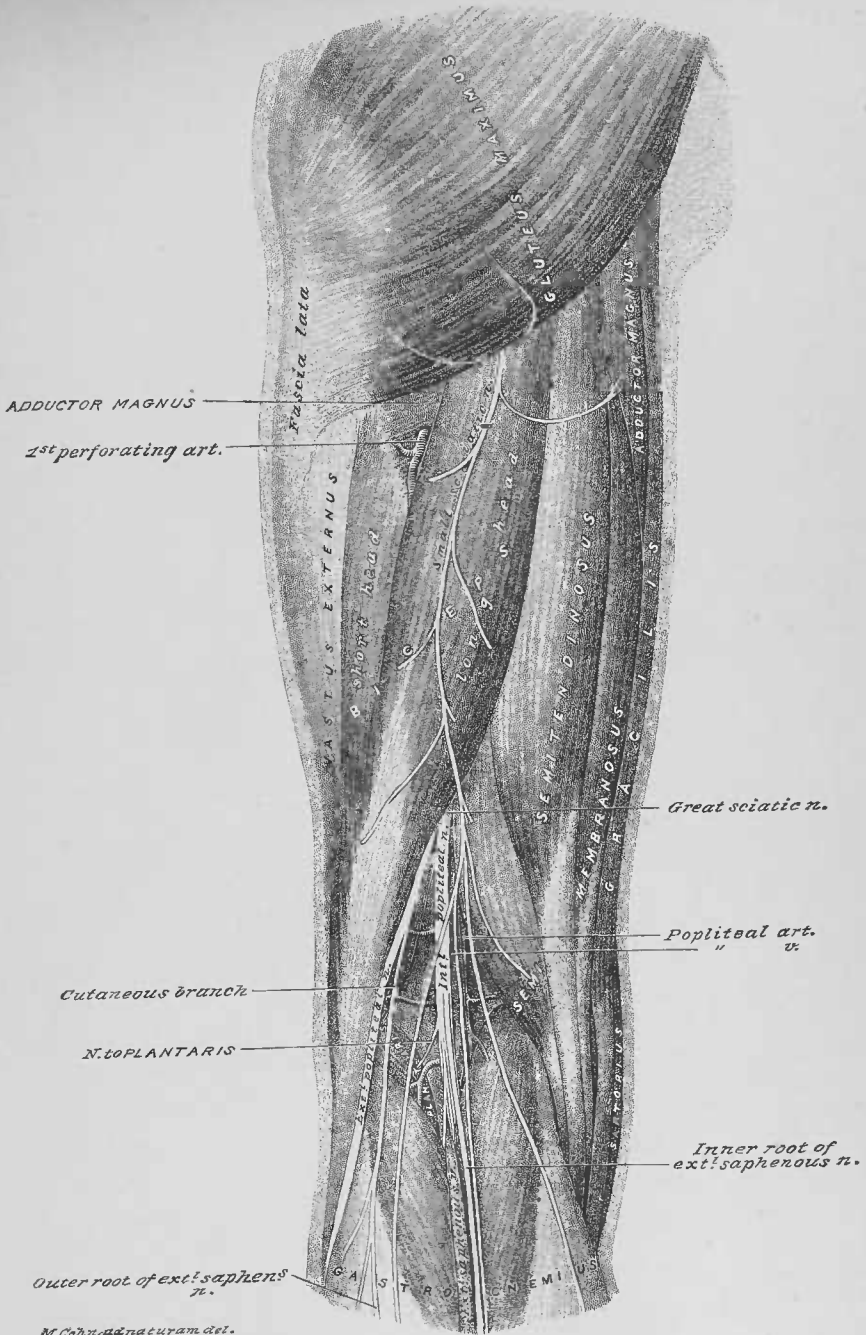
52. Nerve to the Quadratus Femoris Muscle, Plates 99 and 100.—This nerve, from the sacral plexus, emerges from the pelvic cavity by the great sacro-sciatic foramen, from the anterior of the piriformis muscle; it continues inferiorly, upon the bone (ischium), anterior to the gemellus superior, obturator internus, and gemellus inferior muscles; it sends a branch to the gemellus inferior muscle, and its terminal portion enters the anterior surface of the quadratus femoris muscle. It is accompanied by a small branch from the sciatic artery.

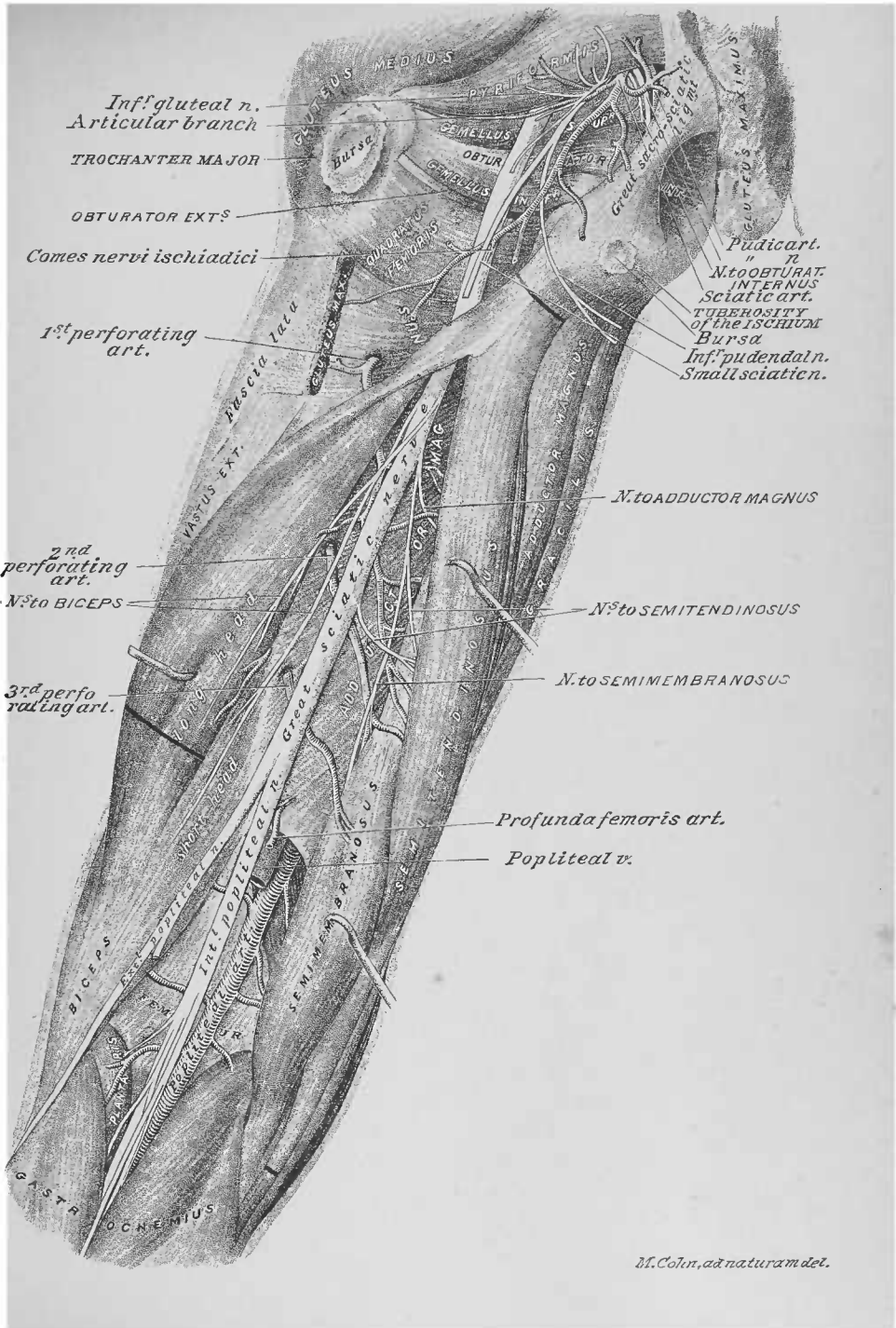
53. Parts Emerging at the Great Sacro-Sciatic Foramen, Plate 100.—The parts emerging from this foramen are: the piriformis muscle; the pudic, the gluteal, and the sciatic arteries, with their comites veins; the great sciatic, the inferior and superior gluteal, the small sciatic, and the pudic nerves; also the nerves to the obturator internus and the quadratus femoris muscles.

54. Parts Passing through the Small Sacro-Sciatic Foramen.—The parts passing through this foramen are: from within outwards, the obturator internus muscle; from without inwards, the pudic artery and vein, the pudic nerve, and the nerve to the obturator internus muscle.

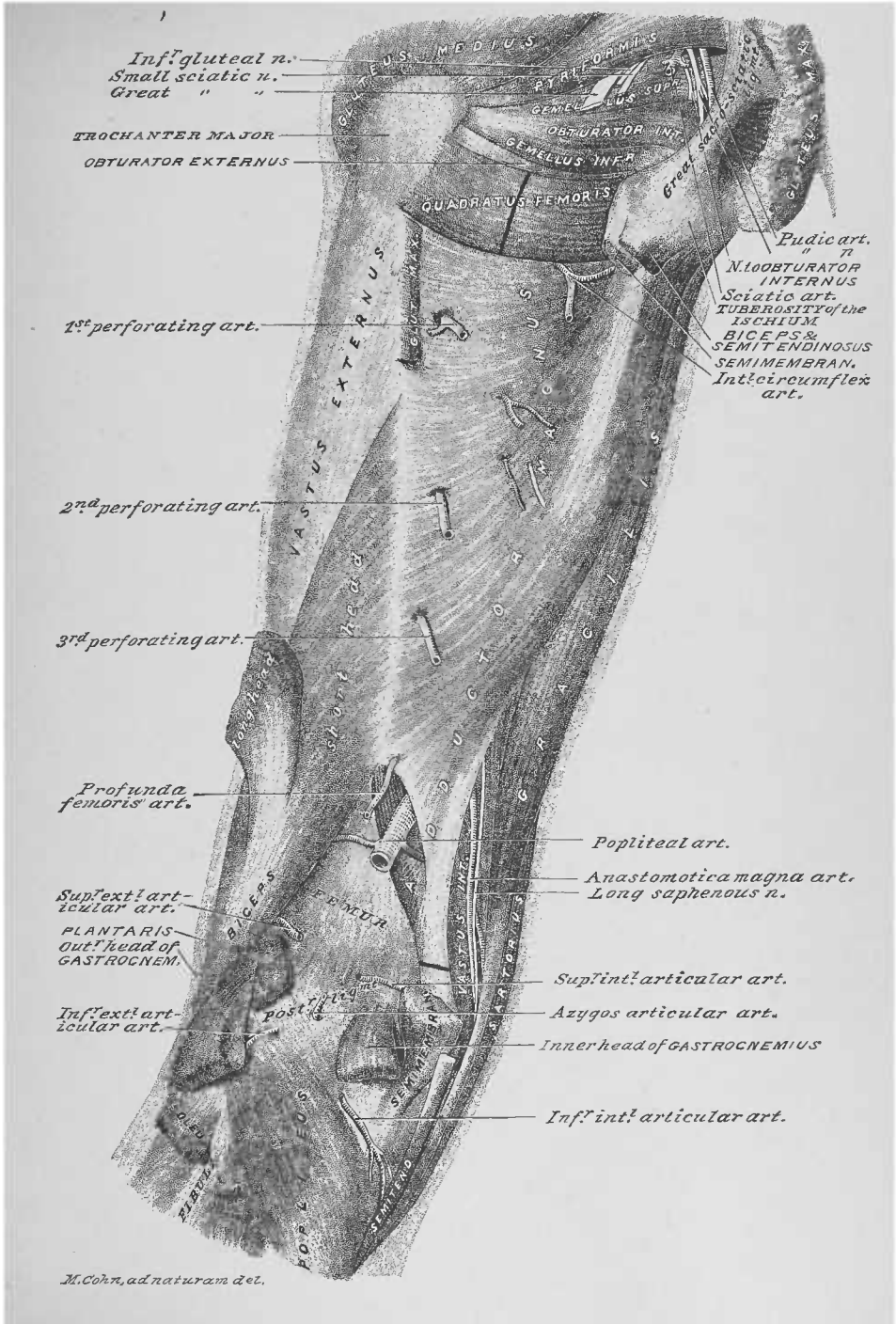


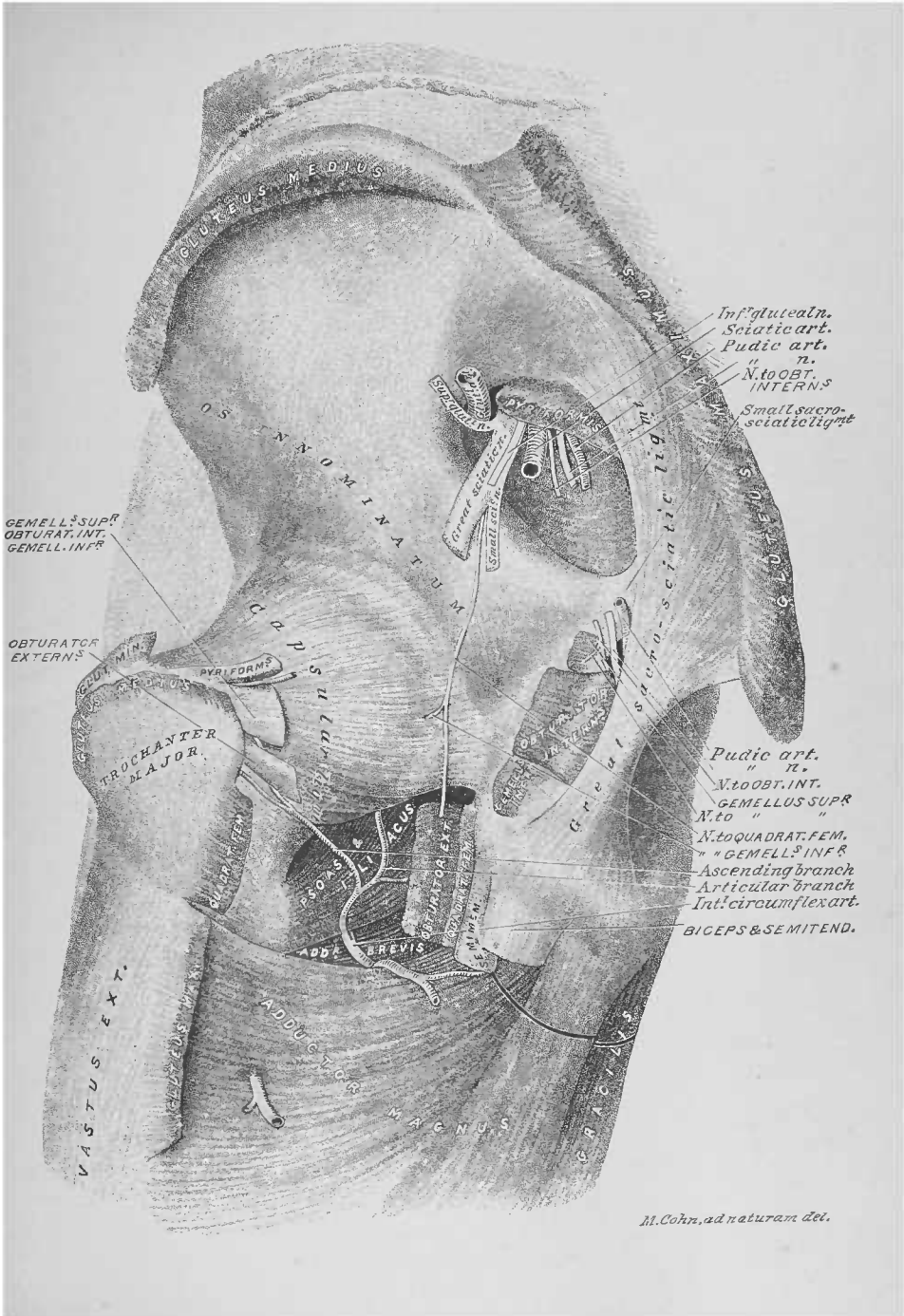






M. Colin, ad naturam del.





M. Cohn, ad naturam dei.

FOURTEENTH DISSECTION.

ARTICULATIONS OF ANKLE, FOOT, LEG, KNEE, AND HIP.

DISSECTION.—At this stage of the dissection of the lower extremity the vertebral column should be disarticulated, between the fourth and fifth lumbar vertebræ, so as to allow the limbs to be turned, as the dissection of their articulations may require. (The dissectors of the back will by this time have completed their work.)

ARTICULATION OF THE ANKLE.

DISSECTION.—Raise the knee by blocks so as to flex it over them, and allow the foot to rest on the table.

Terms of Relation.—The terms *distal* (from the trunk), *proximal* (toward the trunk), *anterior surface*, *posterior surface*, *inner side*, and *outer side* will be used.

Bones of the Ankle-Joint, Plates 68 and 83.—The bones directly concerned in the construction of this joint are: the astragalus at its distal side; the articulated tibia and fibula (by the inferior (distal) tibio-fibular articulation) at its proximal side. The calcaneum contributes to this joint, in affording partial attachments to its lateral ligaments.

DISSECTION.—Clear the surfaces of the external lateral, the internal lateral, and the anterior ligaments.

1. External Lateral Ligament, Plates 101 and 103.—This ligament has its proximal attachment to the distal end of the fibula (external malleolus); it spreads, by three slips, to its distal attachments: an anterior, to the outer side of the neck of the astragalus; a middle, to the outer surface of the calcaneum; a posterior, to the outer side of the body of the astragalus.

2. Internal Lateral Ligament, Plates 102 and 103.—This ligament has its proximal attachment to the distal end of the

tibia; it spreads, deltoid-shaped, over the inner side of the ankle-joint to its distal attachment, to the astragalus and the border of the sustentaculum tali of the calcaneum (Plate 75).

3. Anterior Ligament, Plates 101 and 103; Fig. 1, Plate 102.—This ligament has its proximal attachment to the anterior borders of the distal ends of the tibia and fibula; it bridges across the joint, to its distal attachment to the inner, the dorsal, and the outer surfaces of the distal portion of the neck of the astragalus. Some of its superficial fibres are continued to the dorsal surface and the inner side of the scaphoid bone, blending with the dorsal astragalo-scaphoid ligament. At its inner side it meets the internal lateral ligament; at its outer side is the anterior slip of the external lateral ligament.

DISSECTION.—Turn the limb so as to bring the posterior surface of the ankle-joint uppermost; flex the foot. Clear the ligaments at the posterior face of the joint.

4. External and Internal Lateral Ligaments of the Ankle-Joint, Fig. 2, Plate 102.—At the outer side of the posterior face of the ankle-joint is seen the posterior slip of the external lateral ligament; at its inner side the posterior border of the internal lateral ligament presents.

5. Posterior Ligament.—This ligament consists of scattered fibres that pass from the outer lip of the groove on the posterior surface of the distal end of the tibia (for the tendons of the flexor longus digitorum and the tibialis posticus muscles), to the posterior surface of the body of the astragalus.

ARTICULATIONS OF THE FOOT.

DISSECTION.—Place the limb in the same position as for the dissection of the ankle-joint (page 177). Cut the tendons of the tibialis posticus and the tibialis anticus muscles, as in Plate 103; reflect their proximal portions to the proximal side of the ankle, where they may be cut.

Terms of Relation.—The terms *plantar surface*, *dorsal surface*, *outer side*, *inner side*, *proximal* (toward the heel), and *distal* (from the heel) will be applied to indicate position and direction of ligaments. The regions of the foot will be designated as *digital*, *metatarsal*, and *tarsal*.

Bones of the Foot, Plates 68 and 75.—Twenty-six bones enter into the construction of the foot. In the digital region there are fourteen (page 123). In the metatarsal region five: the *five metatarsals*. In the tarsal region seven: the *three cuneiform*—internal, middle, and external; the *cuboid*; the *scaphoid*; the *calcaneum*; and the *astragalus*. The dorsal, the plantar, and some of the lateral surfaces of the bones present areas for the attachments of ligaments.

Articulations of the Foot.—The twenty-six bones of the foot form the following articulations: the *nine digital*, by which the fourteen bones of the digital region are arranged into the five digits; the *five metatarso-phalangeal*, which join the digits to the heads of the metatarsal bones; the *cuneo-metatarsal*, or the joining of the first, second, and third metatarsals with the internal, middle, and external cuneiform, respectively; the *cubo-metatarsal*, the contiguity of the fourth and fifth metatarsals with the cuboid; the *intercuneiform*, the three cuneiform with each other; the *cubo-cuneiform*, the cuboid with the external cuneiform; the *scapho-cuneiform*, the three cuneiform with the scaphoid; the *scapho-cuboid*, the cuboid with the scaphoid; the *calcaneo-cuboid*, the cuboid with the calcaneum; the *astragalo-scaphoid*, the scaphoid with the distal end of the astragalus; the *astragalo-calcaneal*, the superior surface of the calcaneum to the inferior surface of the astragalus.

DISSECTION.—Clear the dorsal, the plantar, and the lateral surfaces of the digital articulations; expose the ligaments at these surfaces respectively.

1. Articulations of the Digits, Plates 104 and 101; Fig. 1, Plate 102.—These nine articulations have each four ligaments: two lateral, a dorsal, and a plantar. The *lateral ligaments* are situated one at either side of each joint, in the dorsal half of the lateral surfaces of the digit. The *dorsal ligament* occupies the dorsal surfaces of the joint between the dorsal borders of the lateral ligaments. (Some authors ignore this ligament, others regard it as the dorsal portion of the synovial membrane of the joint.) The *plantar ligament* (Fig. 2, Plate 104) fills the space between the plantar borders of the lateral ligaments, bridging between the plantar surfaces of the bones forming the joint. It includes a plate of fibro-cartilage,

whose plantar surface is covered by the sheath of the flexor tendons of the digit.

DISSECTION.—Clear the surfaces of the metatarso-phalangeal articulations. Expose the four distal intermetatarsal interosseous ligaments.

2. Metatarso-Phalangeal Articulations.—These joints, five in number, have the same construction as the digital. The plantar ligaments (Figs. 2 and 3, Plate 104) differ from those of the digits in that the plates of fibro-cartilage are much thicker. The two sesamoid bones opposite the joint of the first digit take the place of the fibro-cartilage plates of the joints of the other digits (page 149; Fig. 1, Plate 82).

3. Distal Intermetatarsal Ligaments, Figs. 1 and 2, Plate 104.—These four interosseous ligaments bridge between the plantar halves, of the opposed surfaces, of the distal ends of the metatarsal bones.

DISSECTION.—Expose the dorsal ligaments: intermetatarsal; cuneo-metatarsal; cubo-metatarsal; intercuneiform; cuneo-cuboid; scapho-cuneiform; and scapho-cuboid.

4. Dorsal Intermetatarsal Ligaments, Plates 101 and 103.—These ligaments, three in number, pass between the dorsal surfaces of the proximal ends of the second, third, fourth, and fifth metatarsal bones.

5. Dorsal Cuneo-Metatarsal Ligaments, Plates 101 and 103; Fig. 1, Plate 102.—These ligaments pass from the dorsal surfaces of the first, second, third, and fourth metatarsal bones to the dorsal surfaces of the three cuneiform bones: from the first and second to the internal cuneiform; from the second to the middle cuneiform; from the second, third, and fourth to the external cuneiform. At the inner side of the articulation of the first metatarsal with the internal cuneiform the dorsal cuneo-metatarsal ligament passes to the plantar plane of the joint, to become continuous with its plantar ligament.

6. Dorsal Cubo-Metatarsal Ligaments, Plates 101 and 103.—These ligaments bridge from the bases of the fourth and fifth metatarsal bones to the cuboid bone.

7. Dorsal Intercuneiform and Cuneo-Cuboid Ligaments.

—These ligaments are three in number: two intercuneiform, between the three cuneiform bones; one cuneo-cuboid, between the cuboid and the external cuneiform.

8. Dorsal Scapho-Cuneiform Ligaments, Plates 101 and 103; Fig. 1, Plate 102.—These ligaments, three in number, pass from the internal, middle, and external cuneiform bones to the scaphoid. The internal dorsal scapho-cuneiform ligament continues over the inner border of the foot to the plantar region, where it meets the internal plantar scapho-cuneiform ligament.

9. Dorsal Scapho-Cuboid Ligament, Plates 101 and 103.—This ligament bridges from the inner side of the cuboid to the scaphoid bone.

DISSECTION.—Section the tendons of the peroneus brevis and longus muscles (Plate 103); depress the longus tendon so as to expose its entrance into the groove on the plantar surface of the cuboid bone (Plate 101). Reflect the proximal ends of the peronei muscles to the posterior surface of the fibula, where they may be cut.

10. Tendons of the Peroneus Brevis and the Peroneus Longus Muscles.—These tendons appear along the outer side of the tarsal region of the foot, from the posterior surface of the distal end of the fibula; they pass to their respective attachments, as before described (page 129).

DISSECTION.—Expose the dorsal calcaneo-cuboid ligament; also, the outer borders of the short and long calcaneo-cuboid ligaments of the plantar region,

11. Dorsal Calcaneo-Cuboid Ligament.—This ligament passes from the dorsal surface of the cuboid bone to that of the distal end of the calcaneum. Its fibres are continued upon the outer side of the opposed bones into the plantar region of the foot, where they meet the fibres of the short calcaneo-cuboid ligament.

12. Dorsal Calcaneo-Scaphoid Ligament.—This ligament bridges from the outer side of the scaphoid to the dorsal surface of the distal end of the calcaneum.

13. External Astragalo-Calcaneal Ligament, Plates 101 and 103; Fig. 2, Plate 106.—This ligament is located at the outer

side of the astragalus, from the dorsal surface of the distal, and inner, portion of the calcaneum to the outer side of the neck of the astragalus.

14. Dorsal Astragalo-Scaphoid Ligament, Plates 103 and 101 ; Fig. 1, Plate 102.—This ligament crosses from the dorsal surface and the inner side of the scaphoid to the same surface and side of the head of the astragalus. The superficial fibres of the anterior ligament of the ankle-joint fuse with this ligament, so as to make it appear as if the anterior ligament was attached to the scaphoid bone (page 178). The inner portion of this ligament winds upon the inner face of the joint between the two bones, to the plantar region, where it meets the plantar calcaneo-scaphoid ligament (Fig. 1, Plate 106).

DISSECTION.—Extend the foot, with its plantar surface uppermost. Clear the surface of the ligaments and tendons of the plantar region, cutting away all muscles, vessels, etc.

15. Plantar Intermetatarsal Ligaments, Plate 105 ; Fig. 1, Plate 106.—These ligaments, three in number, bridge between the plantar surfaces of the proximal ends of the second, third, fourth, and fifth metatarsal bones.

16. Long Calcaneo-Cuboid Ligament.—This superficial ligament, of the plantar region, has a proximal attachment to the distal half of the plantar surface of the calcaneum. Its distal attachments are: its deep fibres, to the proximal border of the peroneal groove of the cuboid bone; its superficial fibres spread as expansions across the plantar surface of the tendon of the peroneus longus muscle, which are attached to the proximal ends of all the metatarsal bones—the strongest being those to the third, fourth, and fifth metatarsal bones. The plantar surface of the metatarsal expansions of this ligament affords attachments to the adductor pollicis and the flexor brevis minimi digiti muscles.

17. Tendon of the Tibialis Posticus Muscle, Plate 105.—The plantar portion of the tendon of this muscle was referred to in the eleventh and twelfth dissections (pages 145 and 162). It passes directly to its primary attachment to the tubercle of the scaphoid bone—on its way thereto it projects an attachment to the sustentaculum tali of the calcaneum. Superficial fibres

of the tendon expand: a direct slip passes to the plantar surface of the internal cuneiform bone; a deflected portion passes, to the outer side, to the dorsal surface of the long calcaneo-cuboid ligament, and distally, to the dorsal surface of the tendon of the peroneus longus muscle.

18. Tendon of the Tibialis Anticus Muscle, Fig. 1, Plate 102; Plate 105; Fig. 1, Plate 106.—The tendon of this muscle winds over the inner border of the tarsal region, to its plantar attachments, to the internal cuneiform bone and the proximal end of the first metatarsal bone.

DISSECTION.—Section the long calcaneo-cuboid ligament (Plate 105); reflect the distal portion to its cuboid and metatarsal attachments, and the proximal portion to the calcaneum; cut the ligament away, as in Fig. 1, Plate 106. Demonstrate the course, lodgement, and attachment of the tendon of the peroneus longus muscle, and cut it away (Fig. 1, Plate 106). Cut the tendon of the tibialis posticus muscle; clear away its calcaneal and internal cuneiform expansions; section its outer and distal expansions and trace them to their several attachments. Clear the surfaces of the plantar scapho-cuboid, the short calcaneo-cuboid, and the plantar calcaneo-scaphoid ligaments.

19. Fibro-Osseous Canal for the Tendon of the Peroneus Longus Muscle, Plate 105; Fig. 1, Plate 106.—The plantar portion of this tendon passes from the outer border of the tarsal region, at the cuboid bone, to its attachment to the outer side of the proximal end of the first metatarsal bone. In its first portion, it is lodged in the plantar groove of the cuboid bone; in its second portion, it lies between the expansions of the long calcaneo-cuboid ligament, at its plantar surface, and the expansions of the tibialis posticus tendon, at its dorsal surface. As lodged it is invested by a synovial sheath, which is closed at its outer end (Plate 101).

20. Expansions of the Tendon of the Tibialis Posticus Muscle, Fig. 1, Plate 106.—The plantar attachments of this tendon have been partly described above—to the scaphoid, the calcaneum, and the internal cuneiform bones. The deflected portion may now be traced: to the cuboid bone; to the middle and external cuneiform bones; and to the proximal ends of the metatarsal bones, second to fifth, inclusive.

21. Plantar Scapho-Cuboid Ligament.—This ligament passes from the cuboid to the scaphoid bone.

22. Short Calcaneo-Cuboid Ligament, Plate 105; Fig. 1, Plate 106.—This ligament is located at the dorsal surface of the long ligament. It is a short band of fibres between the plantar surfaces of the two bones. At its outer side it meets the fibres of the dorsal calcaneo-cuboid ligament (page 181; Plate 101), that are continued over the outer border of the tarsus.

23. Plantar Calcaneo-Scaphoid Ligament.—This is a strong band of fibrous tissue, which bridges from the calcaneum to the scaphoid bone; on its dorsal surface is lodged the head of the astragalus. At its inner border it is met by the fibres of the dorsal astragalo-scaphoid ligament (page 182; Fig. 1, Plate 102), that are continued over the inner border of the tarsal region.

DISSECTION.—Dissect away the metatarsal expansions of the tendon of the tibialis posticus muscle (Fig. 1, Plate 106). Expose the plantar cubo-metatarsal, cuneo-metatarsal, intercuneiform, cuneo-cuboid, and scapho-cuneiform ligaments.

24. Plantar Cubo-Metatarsal Ligaments, Fig. 1, Plate 106.—These ligaments unite the fifth and fourth metatarsal bones to the cuboid bone.

25. Plantar Cuneo-Metatarsal Ligaments.—These ligaments pass from the plantar surfaces of the proximal ends of the first, second, and third metatarsal bones to those of the internal, middle, and external cuneiform bones.

26. Plantar Intercuneiform Ligaments.—These ligaments, two in number, bridge between the plantar surfaces of the three contiguous cuneiform bones, as do the dorsal ligaments (Plate 103); they are not as well marked as the dorsal.

27. Plantar Cuneo-Cuboid Ligament.—This ligament crosses from the plantar surface of the cuboid to the same of the external cuneiform bone.

28. Plantar Scapho-Cuneiform Ligaments.—These ligaments, three in number, bind the three cuneiform bones to the scaphoid bone.

DISSECTION.—Disarticulate the metatarsal bones from the three cuneiform and the cuboid bones; cut apart the bases of the metatarsal bones; disarticulate the cuboid and scaphoid bones from the calcaneum and astragalus; sep-

arate the scaphoid from the cuboid; stand the three cuneiform and the cuboid bones upon their distal surfaces, clear away their plantar ligaments, and spread the bones apart (Fig. 3, Plate 106); section the ligaments of the ankle-joint; turn off the astragalus from the calcaneum (Fig. 2, Plate 106). In making these disarticulations note the interosseous ligaments that present passing between the opposed surfaces of the bones.

29. Interosseous Ligaments of the Metatarsus and Tarsus.

—Between the surfaces of the bases of the metatarsal bones are four proximal interosseous ligaments (Fig. 3, Plate 104). Ligaments unite the internal cuneiform to the second metatarsal, and the external cuneiform to the fourth metatarsal. At the opposed angles of the scaphoid and cuboid bones a ligament passes, and an offshoot from it joins them to the contiguous angle of the calcaneum. Between the plantar halves of the opposed surfaces of the three cuneiform and the cuboid bones ligaments bridge (Fig. 3, Plate 106). A posterior astragalo-calcaneal ligament passes from the dorsum of the calcaneum to the posterior border of the astragalus (Fig. 2, Plate 102). The opposed surfaces of the calcaneum and the astragalus are united by an interosseous ligament (Fig. 2, Plate 106).

ARTICULATIONS OF THE TIBIA AND FIBULA.

Terms of Relation.—Same as for the description of the ankle-joint (page 177).

Bones and Articulations, Fig. 1, Plate 67; Plate 83.—The bones are: the tibia and the fibula. The articulations are: the inferior (distal) tibio-fibular and the superior (proximal) tibio-fibular; the shafts of the bones are bound to each other by an interosseous ligament.

DISSECTION.—Clear the anterior and posterior surfaces of the inferior (distal) tibio-fibular articulation. Dissect away the posterior (inferior) distal tibio-fibular ligament, so as to expose the interosseous ligament of the joint.

1. Inferior (Distal) Tibio-Fibular Articulation, Plates 101 and 103; Fig. 2, Plate 102.—This articulation is formed by the distal ends of the fibula and tibia. Its ligaments are: anterior, posterior, and interosseous. The *anterior inferior (distal) tibio-fibular ligament* extends, obliquely, from the anterior and inner border of the distal end of the fibula to the anterior and

outer border of the distal end of the tibia. The *posterior inferior (distal) tibio-fibular ligament* bridges, obliquely, from the inner lip of the groove (for the tendons of the peroneus longus and brevis muscles) on the posterior surface of the distal end of the fibula, to the posterior surface of the distal end of the tibia. Cutting away the last-described ligament the *inferior (distal) interosseous tibio-fibular ligament* is seen between the opposed surfaces of the bones.

DISSECTION.—Clear the anterior and posterior surfaces of the shafts of the tibia and fibula, and those of the tibio-fibular interosseous ligament between them. Note the areas of the muscle attachments.

2. Muscle Attachments to the Shafts of the Tibia and Fibula and to the Interosseous Ligament, Plates 67 and 83.—

To their posterior surfaces are attached: the flexor longus digitorum, the tibialis posticus, the soleus, and the popliteus, to the tibia; the flexor longus pollicis, the tibialis posticus, and the soleus, to the fibula; the tibialis posticus, to the interosseous ligament. To the outer surface of the fibula: the peroneus longus and the peroneus brevis muscles. To the anterior and inner surfaces of the fibula the extensor longus digitorum, peroneus tertius, and flexor proprius pollicis muscles. To the outer surface of the tibia: the tibialis anticus muscle.

3. Tibio-Fibular Interosseous Ligament, Fig. 1, Plate 67; and Plate 83.—This ligament bridges from the inner border of the shaft of the fibula to the outer border of the shaft of the tibia. It presents a distal opening for the transit of the anterior peroneal artery (page 162; Plate 90); a proximal one for the anterior tibial artery (page 132; Plate 74); and intermediate ones for branches of the anterior tibial artery.

DISSECTION.—Clear the anterior and posterior surfaces of the superior (proximal) tibio-fibular articulation. Preserve the stumps of the attachments of the soleus and biceps muscles, to the fibula; also, the external lateral and posterior ligaments of the knee-joint.

4. Superior (Proximal) Tibio-Fibular Articulation, Plate 107; Fig. 2, Plate 108; Fig. 1, Plate 109.—This joint is formed by the opposing of the proximal end of the fibula to the facet on the distal surface of the outer tuberosity of the tibia. The ligaments are: an anterior and a posterior. The *anterior*

superior (proximal) tibio-fibular ligament passes from the inner border of the anterior surface of the proximal end of the fibula to the outer tuberosity of the tibia. The *posterior superior (proximal) tibio-fibular ligament* bridges from the border of the posterior surface of the proximal end of the fibula to the outer tuberosity of the tibia. The external lateral ligament of the knee-joint, by its distal attachment to the proximal end of the fibula, is accessory to this joint (Fig. 1, Plate 107).

ARTICULATION OF THE KNEE.

Terms of Relation.—The terms in the description of this articulation are those used for the ankle (page 177).

Bones of the Knee-joint, Plates 59, 83, and 91.—The bones which enter into the construction of the knee-joint are: the tibia, the femur, and the patella, directly; with the fibula, indirectly, in its affording attachment to a ligament of the joint.

DISSECTION.—Clear the posterior, the lateral, and the anterior surfaces of the knee-joint, preserving the muscle attachments in its vicinity.

1. Muscle Attachments to the Surfaces of the Knee, Plates 59, 67, 83, 107, 108, and 109; Figs. 1 and 2 of Plate 110.—To the *tibia* are attached: the quadriceps extensor femoris muscle (page 115), at the tubercle of the bone (ligamentum patellæ) and at the antero-lateral surfaces of the tuberosities (lateral expansions of the aponeurosis); the compound aponeurosis of the sartorius, the semitendinosus, and the gracilis muscles to the antero-lateral face of the inner tuberosity; the semimembranosus and the popliteus, to the posterior surface of the inner tuberosity. To the *fibula*: the biceps and the soleus. To the *patella*: included as this bone is (sesamoid bone) in the compound aponeurosis of the quadriceps extensor femoris muscle, it receives, at the anterior surface of its proximal and lateral borders, the four muscles contributed to the aponeurosis (Plate 59); the latter projects from its distal tip and lateral borders as the ligamentum patellæ and lateral expansions of the aponeurosis. To the *femur*: the plantaris and gastroc-

nemius (outer head), to the proximal side of the outer condyle ; the adductor magnus and gastrocnemius (inner head), to the proximal side of the inner condyle ; the popliteus, to the outer face of the outer condyle (Fig. 2, Plate 110).

2. Posterior Ligament, Fig. 2, Plate 108.—This ligament has its distal attachment to the tibia ; its proximal attachment is to the femur, at the proximal side of its condyles. It meets on either side the posterior borders of the respective lateral ligaments of the joint. At its inner side it is contributed to by the tendon of the semimembranosus muscle (page 171). At its middle it is perforated by the azygos articular branch of the popliteal artery, and by the articular branches from the internal popliteal and obturator (page 118 ; Plate 64) nerves.

3. External Lateral Ligament, Fig. 1, Plate 107.—This, a short, round ligament, bridges from the proximal end of the fibula to the outer condyle of the femur.

4. Tendon of the Popliteus Muscle, Fig. 1, Plate 107 ; Fig. 2, Plate 108 ; Fig. 1, Plate 109 ; Fig. 2, Plate 110.—The proximal attachment of this muscle is to the outer condyle of the femur, within the ligaments of the joint ; its tendon winds to the posterior surface of the knee, where it emerges from within the ligaments, at a point between the external lateral ligament and the border of the outer fibro-cartilage of the joint ; in its course it is attached to the convex border of the latter. The muscle expands, as it passes to its distal attachment, to the posterior surface of the proximal end of the tibia (Plates 88, 90, and 98).

5. Internal Lateral Ligament, Fig. 2, Plate 107.—This ligament bridges from the inner tuberosity of the tibia to the inner condyle of the femur ; some of its fibres wind round to be attached to the posterior surface of the tuberosity of the tibia.

6. Anterior Ligament, Plates 64, 65, and 107 ; Fig. 1, Plate 108 ; Fig. 2, Plate 109.—This ligament was cut at the circumference of the patella, and partly described, at page 116. It is attached to the anterior of the femur proximally to its con-

dyles ; the borders of the patella ; and the anterior borders of the tibial tuberosities and the lateral ligaments. Interiorly it is lined by the synovial membrane of the joint.

DISSECTION.—Section the popliteus muscle and the external lateral ligament (Fig. 1, Plate 109) ; then dissect up the proximal end of the tendon of the popliteus muscle and cut it to the proximal side of its attachment to the convexity of the outer fibro-cartilage (Fig. 1, Plate 110). Cut, transversely, through the internal lateral ligament, the posterior ligament, and the anterior ligament of the joint. Manipulate the joint so as to expose the anterior and posterior surfaces of the two crucial ligaments, *in situ*. Section the crucial ligaments ; display their portions, following them to their distal and proximal attachments, respectively. Expose the fibro-cartilages, their transverse and coronary ligaments.

7. Crucial Ligaments, Figs. 1 and 2, Plates 109 and 110.—Flexing the knee-joint, the anterior surfaces of these two ligaments are seen crossing each other between the tibia and femur (Fig. 2, Plate 109) ; extending the joint, their posterior surfaces are exposed (Fig. 1, Plate 109). The *anterior* or *external* bridges from the depression anterior to the spine—between the articular surfaces—of the tibia, to the outer wall of the intercondyloid notch of the femur. The *posterior* or *internal* passes from the depression posterior to the spine—between the articular surfaces—of the tibia, to the inner wall of the intercondyloid notch of the femur. Besides the attachments given of these ligaments, they are, respectively, attached to the contiguous tips of the fibro-cartilages.

8. Fibro-Cartilages, Fig. 1, Plate 110 ; Fig. 2, Plate 109.—These are two semilunar plates of fibro-cartilage, which are thick at their convex and thin at their concave borders ; they are lodged upon the articular surfaces of the inner and the outer tuberosity, respectively, of the tibia ; the inner being the larger of the two. The horns of these fibro-cartilages approach each other, at the depressions anterior and posterior to the spine of the tibia, where they are attached. As before stated, the tibial attachments of the crucial ligaments intervene between the fibro-cartilages ; some of the ligament fibres are attached to their tips. The tendon of the popliteus muscle is attached to the convex border of the outer fibro-cartilage (page 188).

9. Transverse Ligament, Fig. 1, Plate 110.—This ligament passes between the anterior borders of the fibro-cartilages.

10. Coronary Ligament.—This is a circumferential ligament, that bridges from the convexities of the fibro-cartilage plates to the border of the tibia; anteriorly and posteriorly, fibres of the crucial ligaments are continued to it.

ARTICULATION OF THE HIP.

DISSECTION.—Raise the pelvis on a block with its posterior surface uppermost. Cut away all the muscles attached to the surfaces of the os innominatum and the proximal end of the femur.

Terms of Relation.—The general terms of relation (page 2) will be used in the description of the hip-joint.

Bones of the Articulation, Plates 59 and 91.—The femur—head and neck—and the os innominatum—cotyloid cavity (acetabulum)—are the bones forming the ilio-femoral articulation or hip-joint.

DISSECTION.—Clear the posterior surface of the capsular ligament of the joint.

1. Posterior Portion of the Capsular Ligament, Fig. 1, Plate 111.—The posterior portion of the circumference of the neck of the femur, internal to the muscle attachments to the trochanter major and minor of the femur (Plates 99 and 100), affords attachment to the external end of this portion of the capsular ligament. Its internal attachment is to the posterior part of the rim and of the exterior surface of the cotyloid cavity of the os innominatum.

DISSECTION.—Turn the pelvis upon the block with its anterior surface uppermost.

2. Anterior Portion of the Capsular Ligament, Plate 112, and Fig. 1, Plate 66.—The capsular ligament is continued circumferentially from its posterior portion, around the neck of

the femur and the exterior of the cotyloid cavity of the os innominatum. The anterior portion presents a complete sheet of fibrous tissue, in which can be defined three bands: the ilio-femoral band, the ilio-femoral ligament, and the pubio-femoral band. The *ilio-femoral band* forms the superior portion of the capsular ligament, from the internal face of the trochanter major, to the exterior surface of the superior portion of the cotyloid cavity of the ilium. The *ilio-femoral ligament* passes from the anterior surface of the neck of the femur—along the anterior intertrochanteric line—to the anterior portion of the exterior surface of the cotyloid cavity—as high as the anterior-inferior spinous process of the ilium. The *pubio-femoral band* bridges from the neck of the femur, externally and superiorly to the trochanter minor, to the anterior surface of the horizontal ramus of the pubic portion of the os innominatum, internally to the attachment of the ilio-femoral ligament.

DISSECTION.—Section the anterior, the superior, and the inferior portions of the capsular ligament, circumferentially; fold its inferior and external portions back, like the sleeve of a coat, upon the trochanters of the femur; slit its superior part, as in Fig. 2, Plate 111, and reflect the portions, internally. Dislocate the head of the femur from the cotyloid cavity, and allow the femur to hang by the ligamentum teres and the posterior portion of the capsular ligament.

3. Cotyloid Fibro-Cartilage (Cotyloid Ligament), Fig. 2, Plate 111; Fig. 3, Plate 110.—This is a circumferential fibro-cartilage, that rims the border of the cotyloid cavity. When the head of the femur is lodged in the cotyloid cavity, it applies itself to it—like a tight india-rubber band—and holds the ball-like head of bone into the socket of the joint.

4. Ligamentum Teres.—This is an interosseous ligament, that passes from a depression in the inferior half of the convexity of the head of the femur, to the internal portion of the cotyloid cavity of the os innominatum.

5. Transverse Ligament.—This is the name given to that portion of the cotyloid fibro-cartilage, that bridges across the notch at the internal border of the cotyloid cavity. Its interior surface is articular, being applied to the circumference of the head of the femur.

DISSECTION.—Section the ligamentum teres and the posterior portion of the capsular ligament, thus removing the femur and exposing the cotyloid cavity. Cut the transverse ligament from its superior attachment to the cotyloid notch and reflect it, inferiorly, as in Fig. 3, Plate 110; demonstrate the cotyloid attachment of the ligamentum teres to the interior surface of the transverse ligament. Expose the articular branch of the obturator artery and nerve, respectively, that pass through the cotyloid notch, into the ligamentum teres; also the articular branch of the internal circumflex artery.

6. Cotyloid Cavity.—This is a half-egg shaped cavity, at the exterior of the os innominatum, having an articular and a non-articular portion. The *articular portion* occupies the circumference of the interior of the cavity, from the free border thereof, inwardly—with a deficiency at the notch; it is applied, when articulated, to the circumference of the head of the femur. The *non-articular portion* is at the internal part of the cavity, forming an oval depression; when the head of the femur is articulated, this portion of the cavity allows the ligamentum teres to be lodged without being compressed.

7. Cotyloid Attachment of the Ligamentum Teres.—This attachment of the ligament is to the non-articular part of the cotyloid cavity and to the interior of the transverse ligament, directly opposite the foramen formed by the notch and the transverse ligament.

8. Cotyloid Notch, Plate 59; Fig. 3, Plate 110.—This notch is a gap in the internal wall of the cotyloid cavity, which the transverse ligament portion of the cotyloid fibro-cartilage converts into a foramen. The concavity of the notch is at the level of the non-articular portion of the cotyloid cavity.

9. Articular Arteries and Nerve, Fig. 3, Plate 110.—The obturator and the internal circumflex arteries have, each, an articular branch, which supply the joint, by entering the cotyloid notch to reach the ligamentum teres; one is larger than or may take the place of the other. The obturator nerve supplies an articular branch, which accompanies the articular vessels into the joint.

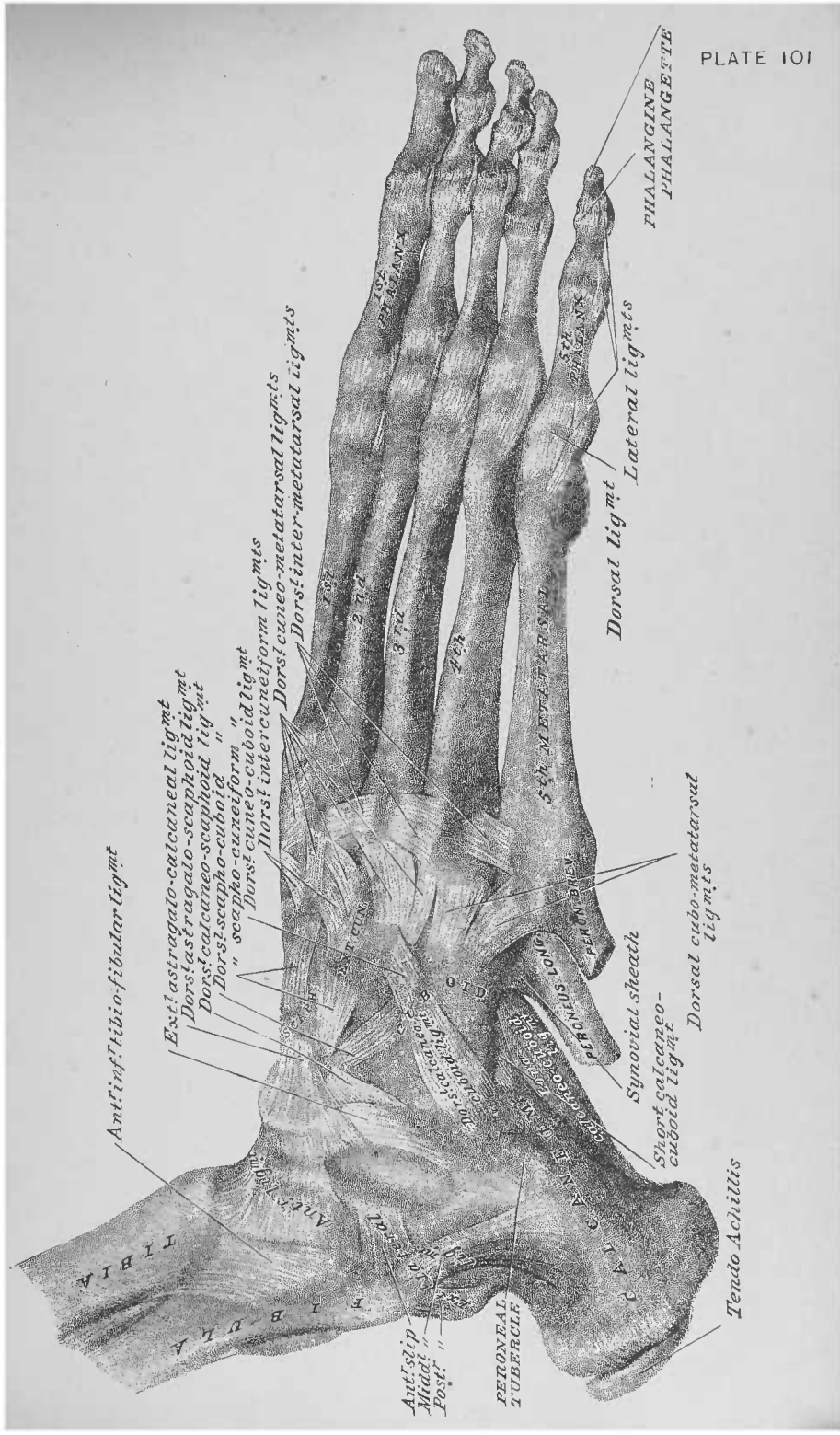


FIG. 1

FIG. 2

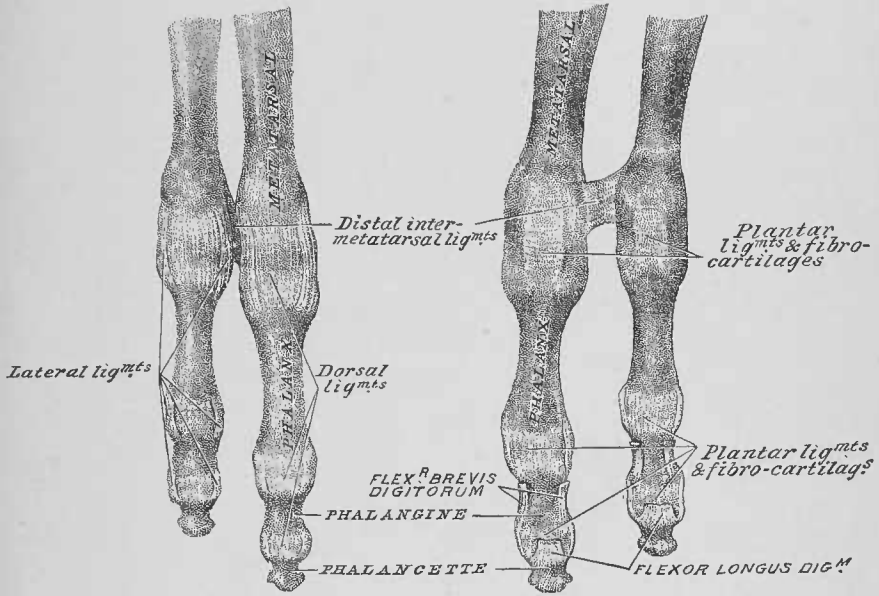
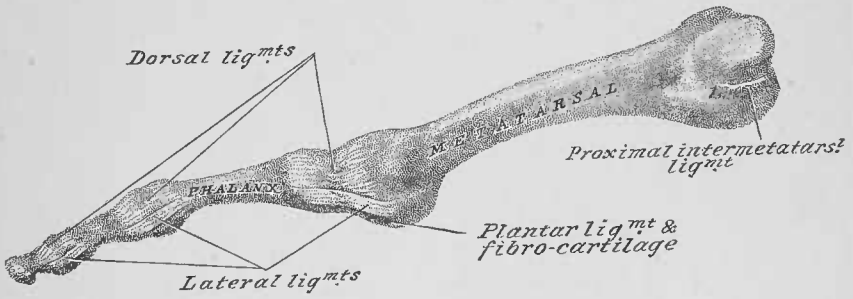
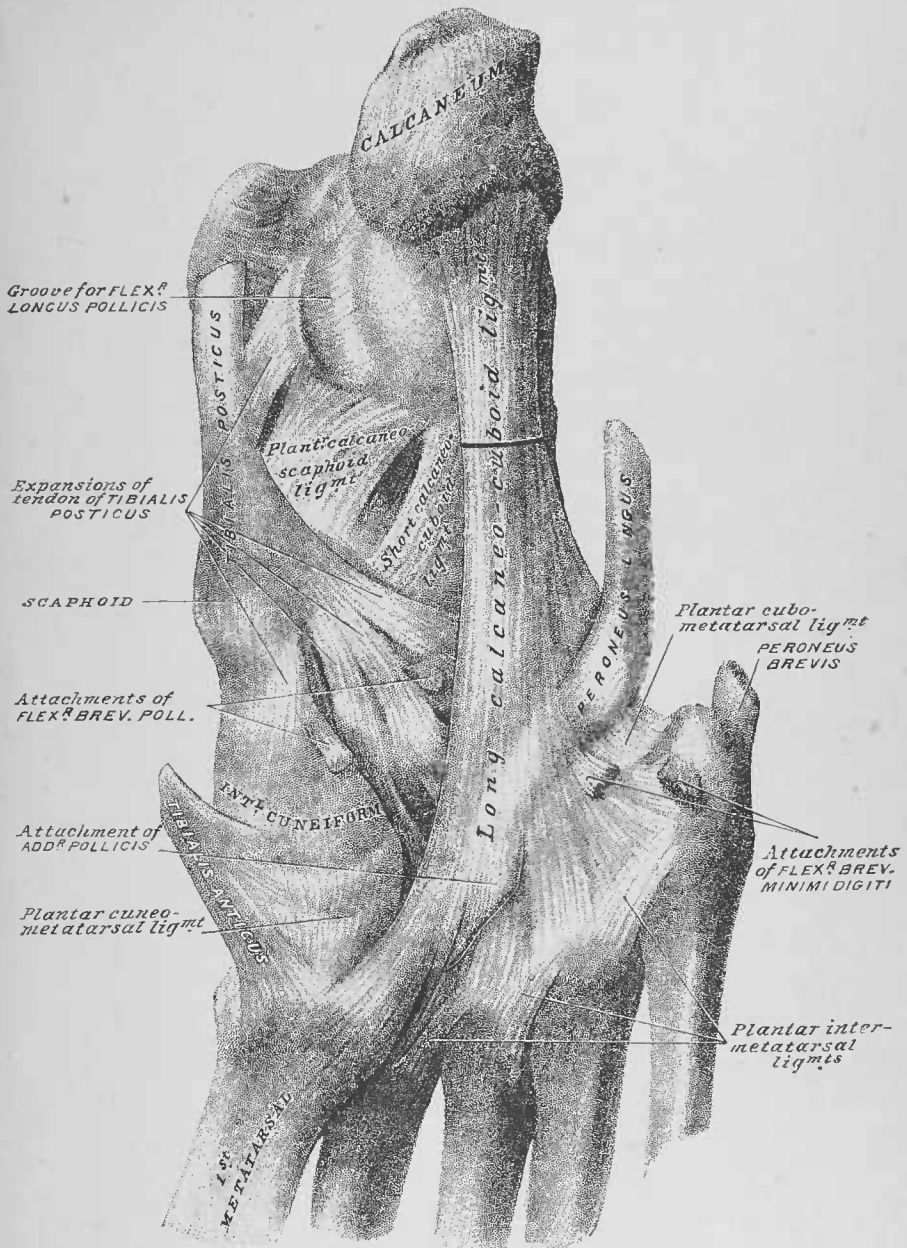


FIG. 3



M. Cohn, ad naturam del.



M. Cohn, ad naturam del.

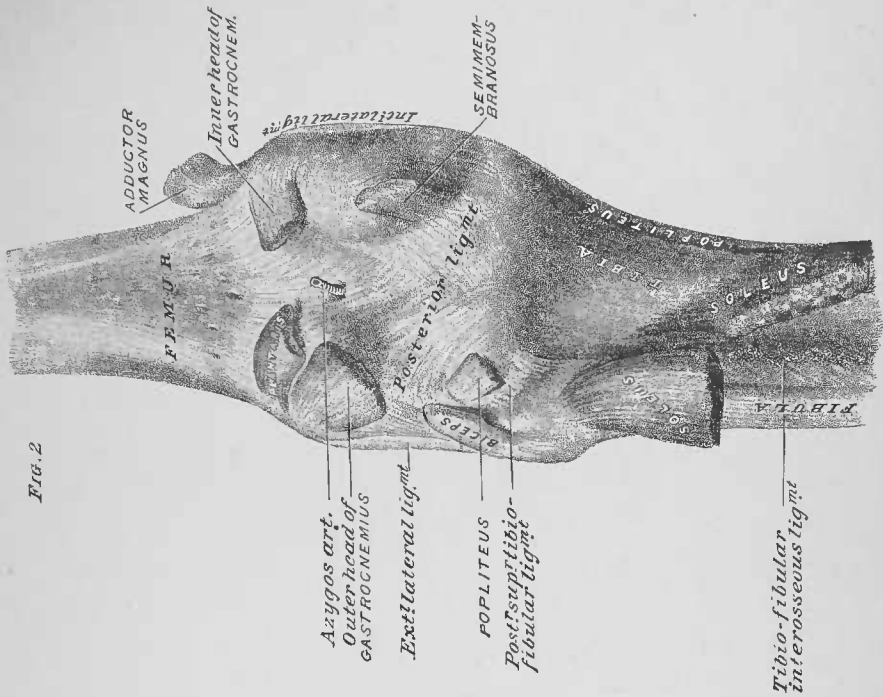


FIG. 2

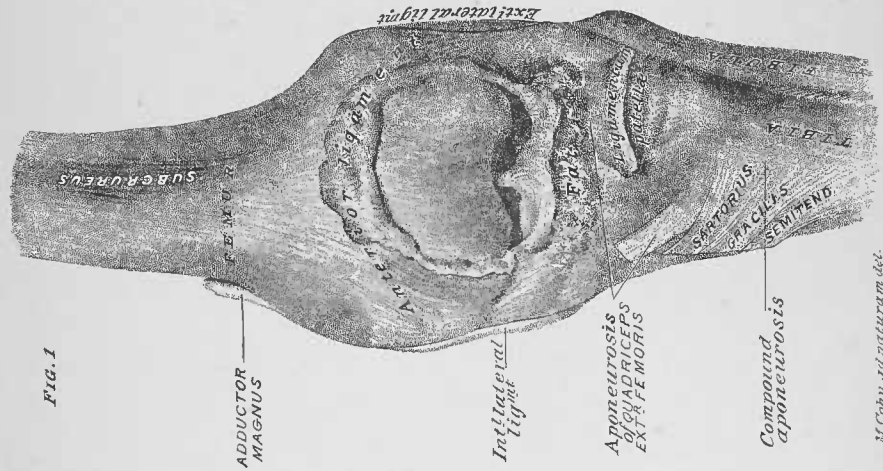


FIG. 1

M. Cohn, a. d. naturam del.

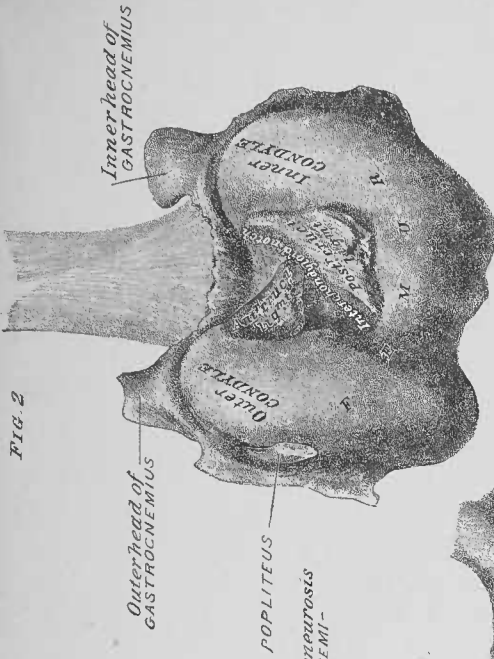


FIG. 2

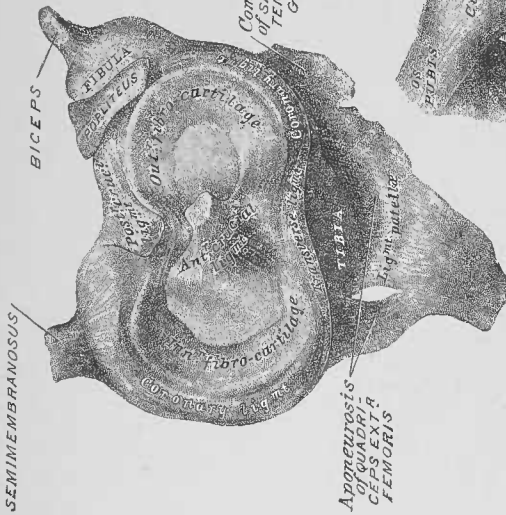


FIG. 1

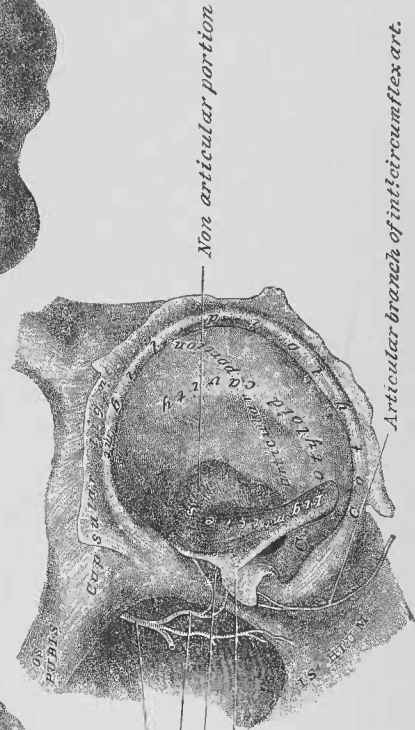


FIG. 3

H. C. W. and H. W. H. del.

QM34
W432p
1888
v.2

545.0294129

DEDALUS - Acervo - ICB

Practical human anatomy :



12100003992

I. C. B. - BIBLIOTECA

TRANSF. F. M. - D PT. ANATOMIA

DA A 17111075 178f

Chicago Medical Times, May, 1889.

"Ashton's Obstetrics embodies the whole subject in a nut-shell. We cordially recommend it to our readers."

Southern California Practitioner, Nov., 1889.

"Morris' Materia Medica.—We know of no better complement for the busy medical student to a course of lectures on Materia Medica than the above book."

Medical and Surgical Reporter, February, 1889.

"Martin's Surgery contains all necessary essentials of modern surgery in a comparatively small space. Its style is interesting and its illustrations admirable."

From Journal of the American Medical Association, Nov. 23d, 1889.

"Hare's Physiology.—An excellent work; admirably illustrated. Well calculated to lighten the task of the overburdened undergraduate."

Pharmaceutical Era, January, 1890.

"Wolf's Chemistry.—The Author, from his intimate acquaintance with medical students, appreciates their necessities in the line of chemical knowledge; the scope of the work is certainly equal to that of the best course of lectures on medical chemistry, which it will also valuably supplement."

Extract from London Lancet, July 6th, 1889.

"Useful Adjuncts to Systematic Reading.—It is fortunate for the Student that these books should be undertaken by competent hands, by men who, being themselves engaged in teaching, know where the subjects require most elucidation, and who, moreover, are careful to be accurate in their statements."

NOW READY.

Saunders' Question-Compends Nos. 10 and 11.

Price; Cloth, \$1.00; Interleaved, for Notes, \$1.25.

No. 10. Essentials of Gynecology. Profusely Illustrated. By EDWIN B. CRAGIN, M. D.

No. 11. Essentials of Diseases of the Skin. 75 Illustrations. By HENRY W. STELWAGON, M. D.

Price; Cloth, \$2.00, net; Interleaved, for taking Notes, \$2.50, net.

SYLLABUS OF OBSTETRICAL LECTURES

IN THE MEDICAL DEPARTMENT
OF THE UNIVERSITY OF PENNSYLVANIA.

BY RICHARD C. NORRIS, M. D.

Price; Cloth, 75 cts.; Interleaved, for Notes, \$1.00.

EXAMINATION OF THE URINE,

FOR CLINICAL PURPOSES.

Colored Plate and Numerous Other Illustrations.

BY LAWRENCE WOLFF, M. D.

New York Medical Record, May 25th, 1889.

"Saunders' Question-Compends are all arranged in the form of questions and answers, and are concise, without the omission of any essential facts. Handsome binding, good paper and clean type increase their attractiveness."

Cincinnati Medical News, January, 1889.

"Wolf's Chemistry.—A little work that can be carried in the pocket, for ready reference in solving difficult problems."

Indiana Medical Journal, December, 1889.

"Semple's Pathology and Morbid Anatomy.—An excellent compend of the subject from the points of view of Green and Payne.

American Practitioner and News, February 16th, 1889.

"Nancrede's Anatomy.—For self-quizzing and keeping fresh in mind the knowledge of Anatomy gained at school it would not be easy to speak of it in terms too favorable."

Gaillard's Medical Journal, November, 1889.

"Morris' Materia Medica.—The very essence of Materia Medica and Therapeutics boiled down and presented in a clear and readable style."

Medical and Surgical Reporter, January 26th, 1889.

"Ashton's Obstetrics.—A work thoroughly calculated to be of service to students in preparing for examination."

PRICE: Cloth, \$1.00; Interleaved, for Taking Notes, \$1.25.

SAUNDERS' QUESTION-COMPENDS.

Arranged in the form of Questions and Answers.

THE ADVANTAGE OF QUESTIONS AND ANSWERS.—The usefulness of arranging the subjects in the form of *questions and answers*, will be apparent, since the student, in reading the standard works, often is at a loss to discover the important points to be remembered, and is equally puzzled when he attempts to formulate ideas as to the manner in which the *questions could be put in the examination-room*.

No. 1.—Essentials of Physiology. Second Edition. Revised and greatly enlarged. By H. A. HARE, M.D., Demonstrator of Therapeutics and Instructor in Physical Diagnosis in the Medical Department, and Instructor in Physiology in the Biological Department, of the University of Pennsylvania, etc., etc.

No. 2.—Essentials of Surgery. Containing also, *Surgical Landmarks, Minor and Operative Surgery, and a Complete Description, together with full Illustration of the Handkerchief and Roller Bandage.* **Second Edition, with ninety Illustrations.** By EDWARD MARTIN, M.D., Instructor in Operative Surgery and Lecturer on Minor Surgery, University of Pennsylvania; Surgeon to the Out-Patients' Department of the Children's Hospital, and Surgical Registrar of the Philadelphia Hospital, etc., etc.

No. 3.—Essentials of Anatomy. Including *Visceral Anatomy*, BASED UPON THE LAST EDITION OF GRAY. **Second Edition.** Over three hundred and fifty pages, with one hundred and seventeen Illustrations. By CHAS. B. NANCYRE, M.D., Professor of Surgery and Clinical Surgery in the University of Michigan, Ann Arbor; Corresponding Member of the Royal Academy of Medicine, Rome, Italy; Late Surgeon Jefferson Medical College, etc., etc.

No. 4.—Essentials of Medical Chemistry. Organic and Inorganic, containing also Questions on Medical Physics, Chemical Physiology, Analytical Processes, Urinalysis and Toxicology. By LAWRENCE WOLFF, M.D., Demonstrator of Chemistry, Jefferson Medical College; Visiting Physician to German Hospital of Philadelphia; Member of Philadelphia College of Pharmacy, etc., etc.

No. 5.—Essentials of Obstetrics. Illustrated. By W. EASTERLY ASHTON, M.D., Demonstrator of Clinical Obstetrics in the Jefferson Medical College, and Chief of Clinics for Diseases of Women in the Jefferson Medical Hospital, etc., etc.

No. 6.—Essentials of Pathology and Morbid Anatomy. Illustrated. By C. E. ARMAND SEMPLE, B.A., M.B. Cantab., L.S.A., M.R.C.P. Lond., Physician to the Northeastern Hospital for Children, Hackney; Professor of Vocal and Aural Physiology and Examiner in Acoustics at Trinity College, London, etc., etc.

No. 7.—Essentials of Materia Medica, Therapeutics and Prescription Writing. By HENRY MORRIS, M.D., late Demonstrator, Jefferson Medical College; Fellow College of Physicians, Philadelphia; Co-Editor Biddle's *Materia Medica*; Visiting Physician to St. Joseph's Hospital, etc., etc.

Nos. 8 and 9.—Essentials of Practice of Medicine. (Double number, over five hundred pages.) By HENRY MORRIS, M.D. With an Appendix on Urinary Analysis by LAWRENCE WOLFF, M.D. Profusely Illustrated. (In preparation.)

No. 10.—Essentials of Gynæcology. With numerous Illustrations. By ERWIN B. CRAIGIN, M.D., Attending Gynecologist, Roosevelt Hospital, Out-Patients' Department; Assistant Surgeon, New York Cancer Hospital, etc., etc.

No. 11.—Essentials of Diseases of the Skin. Illustrated. By HENRY W. STELWAGON, M.D., Physician to Philadelphia Dispensary for Skin Diseases; Chief of the Skin Dispensary in the Hospital of University of Pennsylvania; Physician to Skin Department of the Howard Hospital; Lecturer on Dermatology in the Women's Medical College, Philadelphia, etc., etc.

No. 12.—Essentials of Minor Surgery and Bandaging. With an Appendix on **Veneral Diseases.** Illustrated. By EDWARD MARTIN, M.D., author of the "Essentials of Surgery," etc. (In preparation)

No. 13.—Essentials of Forensic Medicine. Profusely Illustrated. By ARMAND SEMPLE, M.D., author of "Essentials of Pathology and Morbid Anatomy." (In preparation.)

No. 14.—Essentials of the Refraction and the Diseases of the Eye. Illustrated. By EDWARD JACKSON, A.M., M.D., Professor of Diseases of the Eye in the Philadelphia Polyclinic and College for Graduates in Medicine; Member of the American Ophthalmological Society; Fellow of the College of Physicians of Philadelphia; Fellow of the American Academy of Medicine, etc., etc.; and **Essential Diseases of the Nose and Throat.** Illustrated. By E. BALDWIN GLEASON, S. B., M.D., Assistant in the Nose and Throat Dispensary of the Hospital of the University of Pennsylvania; Assistant in the Nose and Throat Department of the Union Dispensary; Member of the German Medical Society, Philadelphia Polyclinic Medical Society, etc., etc. (In preparation.)

N.º 1787.....

QM34

W432p

1888

Autor Weisse, Faneuil D. v.2.....

Titulo Practical human anatomy;

a working guide for ...

NOME	DATA
.....
.....
.....

QM34

W432p

1888

v.2

t.1787

Weisse, Faneuil Dunkin

Practical human anatomy; a working guide for students of medicine and a ready-reference for surgeons and physicians



